

A diprosopus monocephalus tetrophthalmos: a case report and review of literature

Muhammet Erdal Sak¹, Abdulkadir Turgut¹, Sibel Sak², Hidayet Vural¹, Ahmet Yalinkaya¹

¹Department of Obstetrics & Gynecology, Faculty of Medicine, Dicle University, Diyarbakır, Turkey

²Department of Obstetrics & Gynecology, Diyarbakır Maternity & Child Hospital, Diyarbakır, Turkey

Abstract

Objective: The aim of this paper was to present and discuss a case of double-face or diprosopus of a rare variant of conjoined twins.

Case: A 24-year-old patient at 21 weeks of gestation having gravida 3, 2 living children and no significant family history was referred to our clinic with the diagnosis of hydrocephaly. Intrauterine assessment of the obstetric ultrasonography showed the fetus with one head, two faces, one body, two arms and legs, a single, unified spinal cord and vertebral column compatible with 21 weeks of gestation.

Conclusion: With the spread of prenatal follow-up, early detection of cases with conjoined twins, such as diprosopus, is essential in terms of social, economic and ethical aspects, and it will enable parents to decide at early weeks.

Key words: Diprosopus, monocephalus, tetroftalmus.

Bir diprosopus monosefalus tetroftalmus olgusu ve literatürün gözden geçirilmesi

Amaç: Bu makalede yapışık ikizinin nadir bir varyantı olan çift yüz veya diprosopus olgusunu sunmak ve tartışmak amaçlanmıştır.

Olgu: Yirmi dört yaşında gravidası 3 yaşayan 2, özgeçmiş ve soygeçmişinde özellik bulunmayan hasta 21. gebelik haftasında hidro-sefali ön tanısıyla dış merkezden kliniğimize refere edildi. Yapılan obstetrik ultrasonografi değerlendirilmesinde intrauterin 21 hafta ile uyumlu, tek baş, iki yüz, dört göz, tek gövde, iki kol ve bacak, hidrosefalisi bulunan fetüs tespit edildi.

Sonuç: Prenatal takibin yaygınlaşması ile diprosopus gibi yapışık ikiz olgularının erken dönemde tespit edilmesi, sosyal, ekonomik ve etik açıdan önemli olup, ebeveynlerin erken haftalarda karar vermesini sağlayacaktır.

Anahtar sözcükler: Diprosopus, monosefalus, tetraftalmus.

Introduction

Conjoined twins are rare and interesting phenomenon, and the incidence reported for craniofacial duplication or diprosopus (two face, single head and single body) is 180,000/15,000,000.^[1] Conjoined twins have high mortality rate. Approximately 40% of them results in abortion, and 1/3 of the cases die less than 24 hours after birth.^[2,3] Although its etiology is not known well, they have a wide spectrum from double nasal structure to double face, four eyes (tetrophthalmos) and single head (diprosopus monocephalus).^[4]

The oldest diprosopus case known was first stated in the works of Ambroise Pare in 16th century. Many diprosopus cases with single body and normal extremities are complete duplication and there are severe defects in the central nervous system. On the other hand, incomplete diprosopus cases (duplication of maxilla, mandible and oral cavity) have normal central nervous system.^[5] In this study, we aimed to evaluate prenatal diagnosis and management of a diprosopus case diagnosed on 21st week of gestation, through the literature.

Correspondence: Muhammet Erdal Sak, MD. Dicle Üniversitesi Tıp Fakültesi, Kadın Hastalıkları ve Doğum Anabilim Dalı, Diyarbakır, Turkey.
e-mail: drmesak@yahoo.com

Received: September 16, 2013; **Accepted:** Nisan 25, 2013

Available online at:
www.perinataljournal.com/20130212008
doi:10.2399/prn.13.0212008
QR (Quick Response) Code:



Case Report

A 24-year-old patient at 21 weeks of gestation having gravida 3, 2 living children and no significant family history was referred to our clinic with the diagnosis of hydrocephaly from another clinic. In the intrauterine assessment by the obstetric ultrasonography (Voluson 730 PRO, General Electric, Fairfield, Connecticut, USA) of the patient at 21 weeks of gestation showed the fetus with one head, two faces, four eyes (**Fig. 1**), one body, two arms and legs, hydrocephaly, and compatible with intrauterine 21 weeks of gestation. The findings were confirmed by MRI (**Figs. 2 and 3**).

In the transverse and longitudinal views, it was found that fetus had one heart, one stomach, one blad-

der, one placenta and one umbilical cord. The patient and her husband were informed about the condition. The case was discussed in the ethics committee of our clinic. After the written consent of the patient and her husband was obtained, termination was decided. After termination, it was observed in the macroscopic examination that fetus had one head, two faces, one body, two arms and legs (**Fig. 4**). The parent did not allow an examination on fetus after delivery.

Discussion

Conjoined twins are quite rare congenital anomaly seen in 1/50,000-1/100,000 cases.^[6] Our case was a craniofacial duplication or diprosopus case which is a variant of conjoined twins. The conjoined twins are independent from race, heredity, delivery number or kinship.^[7] Although the etiology of conjoined twins is not known well, there are two theories proposed: According to the first theory, monovular embryo is divided incompletely on 13th-15th days of conception. In fusion theory, a secondary fusion occurs among two monovular embryonic disks.^[8]

When fusions with different pattern are compared, central-located conjoined twins are seen more frequently.^[9] Although complex problems within a wide

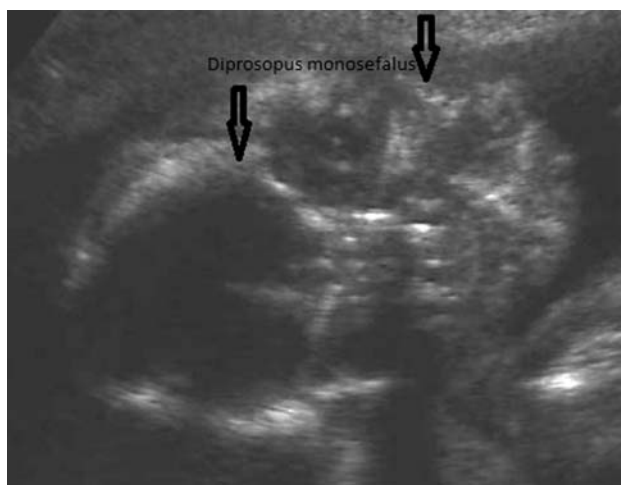


Fig. 1. Ultrasonographic view of double-face, single head.

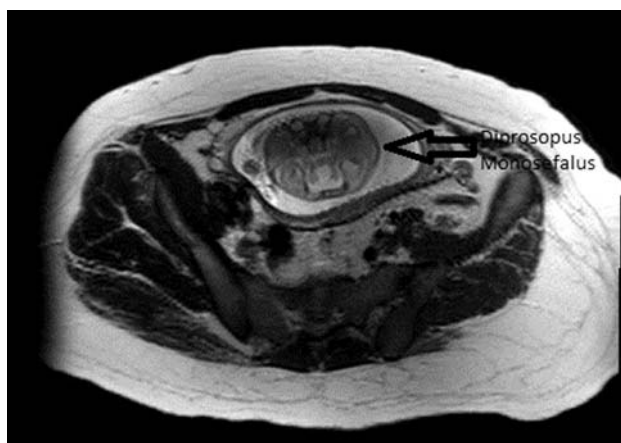


Fig. 2. MRI view of double-face, single head.

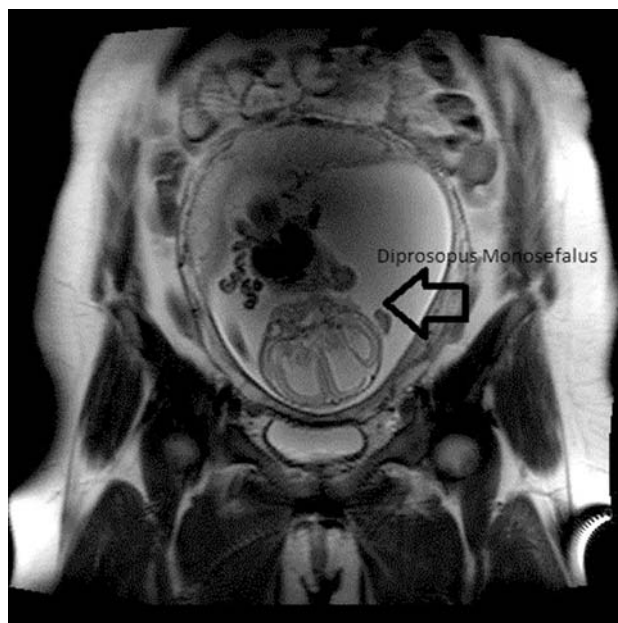


Fig. 3. MRI view of double-face, single head.

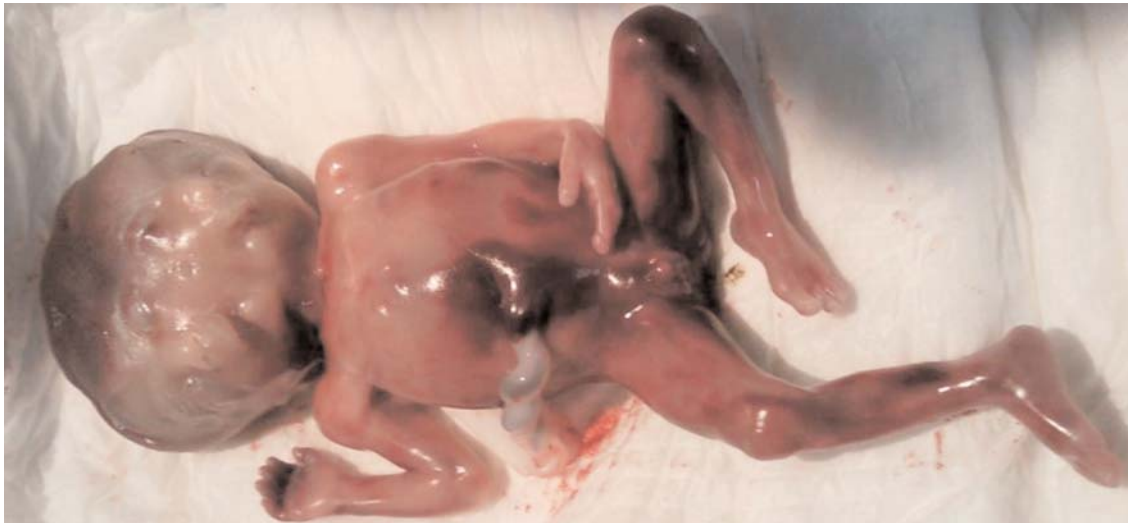

Fig. 4. Diprosopus monocephalus.

spectrum which may include all organ systems are observed in conjoined twins, the most severe anomalies are seen on fusion location. Diprosopus shows full duplication of face structures. Cleft palate and lip anomalies as well as central nervous system, cardiac, gastrointestinal and respiratory system anomalies are observed at a high rate. In our case, there was hydrocephaly. As in our case, generally female gender is dominant.^[10] Chromosomal analysis results of such cases are generally normal. We could not conduct a chromosomal analysis in our case since the parent did not allow.

It is believed that diprosopus occurs as a result of a fault in the neurulation of embryo. Notochord defines the axis of embryo and induces neurulation. Peripheral neural crest cells create mesenchymal connective tissue of face and mouth areas, and pharyngeal arch.^[10] A fault in the neurulation causes neural tube to fail to be closed.^[11] Central nervous system anomalies frequently accompany.^[12] In our case, hydrocephaly was observed as neural tube defect.

Prenatal diagnosis of cases with diprosopus was reported in the first trimester. Maternal alphafetoprotein levels were found to be high in some cases. Low fetoprotein was reported only in a case with cranioschisis.^[13,14] Although polyhydramnios is observed in conjoined twins more frequently as a prenatal sonographic finding compared to normal twins, amniotic fluid

was normal in our case. Interestingly, Onuf mentioned excessive amount of amniotic fluid by the examination before ultrasound.^[15] Other sonographic findings are irregular cranium, enlargement of vertebra, and head in heart shape or with two equal parts.^[13] Facial duplication is shown clearly by sonography.

Central nervous system anomalies were detected in all reported cases with diprosopus. In our case, hydrocephaly and double faces were seen prenatally. Conjoined twins can be recognized at first trimester easily by ultrasonography. If a single yolk sac and two fetuses or monoamniotic twins are observed by ultrasonography, the possibility of conjoined twins should be kept in mind. Cases which have advanced fusion like diprosopus can be recognized in advanced weeks.

Conclusion

Consequently, diprosopus is one of the conjoined twin types and usually central nervous system anomalies accompany it. In our region, diagnosing such cases occur only in advanced weeks of gestation due to irregular prenatal follow-up. With the spread of prenatal follow-up, early detection of cases with conjoined twins, such as diprosopus, is essential in terms of social, economic and ethical aspects, and it will enable parents to decide at early weeks.

Conflicts of Interest: No conflicts declared.

References

1. D'Armiento M, Falletti J, Maruotti GM, Martinelli P. Diprosopus conjoined twins: radiologic, autptic, and histologic study of a case. *Fetal Pediatr Pathol* 2010;29:431-8.
2. Sen C, Celik E, Vural A, Kepkep K. Antenatal diagnosis and prognosis of conjoined twins--a case report. *J Perinat Med* 2003;31:427-30.
3. Baldwin VJ. Pathology of multiple pregnancy. In: Wigglesworth JS, editors. *Textbook of fetal and perinatal pathology*. Vol 1. Oxford: Blackwell Scientific Publications; 1991. p. 221-62.
4. Suhil A. C, Bakshi J, Naseer A. C, Omar K, Roomi Y. Imaging findings in diprosopus tetraophthalmos. A case report. *Fetal Pediatr Pathol* 2010;29:431-8.
5. Carles D, Weichhold W, Alberti EM, Léger F, Pigeau F, Horovitz J. Diprosopus revisited in light of the recognized role of neural crest cells in facial development. *J Craniofac Genet Dev Biol* 1995;15:90-7.
6. Spitz L, Kiely EM. Conjoined twins. *JAMA* 2003;289:1307-10.
7. Spencer R. Anatomic description of conjoined twins: a plea for standardized terminology. *J Pediatr Surg* 1996;31:941-4.
8. Altaş S, Çetinkaya K, Delibaş İ, Taştekin A, Kadanalı S. Bir disefalus parapagus birleşik ikiz olgusu ve literatürün gözden geçirilmesi. *TJOD Dergisi* 2010;7:55-60.
9. Mariona FG. Anomalies specific to multiple gestations. In: Chervenak FA, Isaacson Gc, Campbell S, editors. *Ultrasound in obstetrics and gynecology*. Vol 2. Boston, MA: Little Brown and Co.; 1993. p. 1051-63.
10. Erler A, Koyuncu F, Kurt S, Demir N, Kolday K, Turan E, et al. Yapışık ikizler. *Perinatoloji Dergisi* 1996;4:110-2.
11. Moore KL. *The developing human: clinically oriented embryology*. 4th ed. Philadelphia: W.B. Saunders Company; 1988. p. 53-9.
12. Changaris DG, McGavern MH. Craniofacial duplication (diprosopus). *Arch Pathol Lab Med* 1976;100:392-39.
13. Fontanarosa M, Bagnoli G, Ciolini P, Spinelli G, Curiel P. First trimester sonographic diagnosis of diprosopus twins with craniorachischisis. *J Clin Ultrasound* 1992;20:69-71.
14. Okazaki JR, Wilson JL, Holmes SM, Vandermark LL. Diprosopus: diagnosis in utero. *AJR Am J Roentgenol* 1987;149:147-8.
15. Onuf B. A case of double formation of the face with craniorhachi-schisis involving the whole vertebral column. *Med Rec* 1895;48: 401-4.