

# Central nervous system findings associated with co-twin death in twin pregnancy: correlation between ultrasonography and magnetic resonance findings

Talat Umut Kutlu Dilek<sup>1</sup>, Arzu Doruk<sup>1</sup>, Engin Kara<sup>2</sup>, Saffet Dilek<sup>1</sup>

<sup>1</sup>Department of Obstetrics & Gynecology, Faculty of Medicine, Mersin University, Mersin, Turkey

<sup>2</sup>Department of Radiology, Faculty of Medicine, Mersin University, Mersin, Turkey

## Abstract

**Objective:** In this article, we aimed to discuss central nervous system findings appearing in living fetus after co-twin death in a twin pregnancy and therefore the correlation and its supplementary characteristics between magnetic resonance imaging (MRI) and ultrasonography.

**Case:** Of the thirty-three-year-old patient who was pregnant for the second time, 24x25 mm hyperechogenic view compatible with hemorrhage in frontal horn of the left lateral ventricle was observed in the surviving fetus after in utero loss of monochorionic co-twin at 27 weeks of gestation. It was also found that the adjacent cerebral parenchyma was also in heterogeneous view. In the MRI carried out, hemorrhage indicators reaching to parenchyma and opening to ventricle were observed on bilateral basal ganglions, being more distinct on the left. With these findings, the lesion was evaluated as grade IV germinal matrix hemorrhage. While the woman was pregnant for 29 weeks and 6 days, one male baby which was 1153 g was delivered by cesarean section after the rupture of membrane.

**Conclusion:** Ultrasonography and magnetic resonance imaging complete each other in the diagnosis of the complications of central nervous system appearing in the surviving co-twin after the death of other co-twin. MRI provides better anatomical details for revealing ischemia-associated late sequels.

**Keywords:** Death of co-twin, central nervous system findings, ultrasonography, MRI.

## Özet: İkiz eşi ölümüne bağlı merkezi sinir sistemi bulguları: Ultrasonografi ve manyetik rezonans bulgularının korelasyonu

**Amaç:** Bu yazıda, ikiz eşlerinden birinin ölümü sonrasında sağ kalan fetüste ortaya çıkan MSS bulguları dolayısıyla manyetik rezonans görüntüleme (MRG) ile ultrasonografinin birbiri ile korelasyonu ve tamamlayıcı niteliğini tartışmayı amaçladık.

**Olgu:** Otuz üç yaşında 2. gebeliği olan hastanın, 27 haftalık gebe iken monokoryonik ikiz eşlerinden birinin in utero kaybı sonrasında sağ kalan fetüsünde sol lateral ventrikül frontal hornunda 24x25 mm hiperekojen intraventriküler hematoma ile uyumlu görünüm izlendi. Komşu serebral parankimin de heterojen görünümde olduğu saptandı. Yapılan MRG’de, bilateral bazal ganglionlarda solda daha belirgin olmak üzere parankime uzanan ve ventriküle açılmış hemoraji sinyalleri izlendi. Bu bulgularla lezyon grade IV germinal matriks kanaması olarak değerlendirildi. Yirmi dokuz hafta 6 günlük gebe iken membran rüptürü sonrasında sezaryenle 1 adet canlı, 1153 g erkek bebek doğurtuldu.

**Sonuç:** İkiz eşlerinden birinin ölümüne bağlı sağ kalan ikiz eşinde ortaya çıkan merkezi sinir sistemi komplikasyonlarının tanısında ultrasonografi ve manyetik rezonans görüntüleme birbirinin tamamlayıcısıdır. İskemiye bağlı geç sekellerin ortaya konmasında MRG daha iyi anatomik detaylar sağlar.

**Anahtar sözcükler:** İkiz eşi ölümü, MSS bulguları, ultrasonografi, MRG.

**Correspondence:** Talat Umut Kutlu Dilek, MD. Mersin Üniversitesi Tıp Fakültesi, Kadın Hastalıkları ve Doğum Anabilim Dalı, Mersin, Turkey.  
e-mail: umutdilek@gmail.com

**Received:** September 27, 2013; **Accepted:** December 12, 2013



## Introduction

Death of a co-twin brings about some questions for surviving co-twin as well as the psychological trauma of family by the loss of one fetus.<sup>[1]</sup> In order to answer the questions such as how surviving co-twin is affected and what is the risk for losing the surviving co-twin, it is required to know the chorionicity and the period elapsed until death of one of the co-twins. While the risk to lose one of the co-twins is 2.7% at second trimester, it reaches up to 6.7% at third trimester.<sup>[2]</sup> Mortality and morbidity increases in the surviving co-twin after the death of other co-twin. Morbidity associated with shared circulation is 17-25%.<sup>[3]</sup> Bajoria et al.<sup>[4]</sup> reported that the rate for acute twin-to-twin transfusion syndrome (TTTS) is 25-40% in case of the death of one co-twin. TTTS which arises after placental share and anastomoses causes a series of central nervous system complications resulting bilateral renal cortical necrosis and cerebral palsy in the surviving baby.<sup>[5]</sup>

The possibility of neurodevelopmental complication after the loss of one co-twin increases 4.81 times while abnormal intracranial imaging findings are observed 3.25 times more.<sup>[6]</sup> While thrombogenic materials reaching to surviving fetus through anastomoses from the dead co-twin were held responsible for the complications in the past, it has been recently accepted that they are caused by the hypotension and cerebral ischemia appearing in surviving fetus after acute transfusion.<sup>[7,8]</sup>

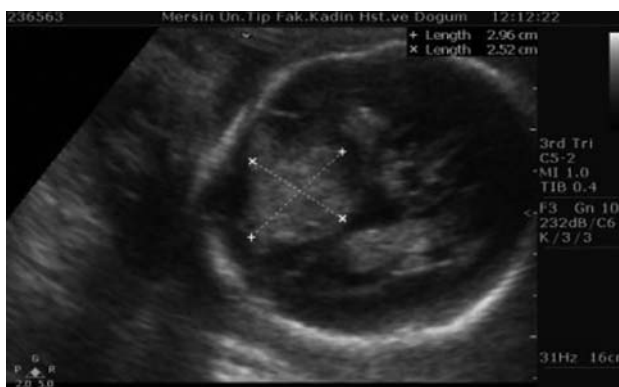Placental vascular architecture and anastomoses enables a tendency for the development of radiological and neurological problems. The occurrence of findings

which can be presented in surviving co-twin by ultrasonography takes 2-3 weeks and delays diagnosis.<sup>[9]</sup> MRI is more effective than ultrasonography for presenting the changes in brain parenchyma, and it becomes widespread for detecting central nervous system findings in such fetuses.<sup>[10]</sup> In this report, we aimed to discuss the correlation and supplementary characteristics between these two techniques.

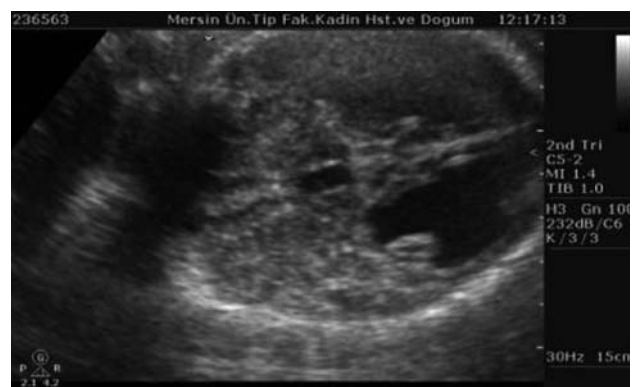## Case Report

While routine antenatal follow-up visits of the thirty-three-year-old patient with gravida 2, para 1, living 1 and spontaneous twin pregnancy were going on, it was found out during her physical and ultrasonographic examinations performed at 27 weeks of gestation that the femur length of the fetus on the right bottom region was compatible with 27 weeks of gestation and had no cardiac activity. Until 2 weeks before the examination where one of the co-twins was in utero exitus, there was no obstetric complication during the follow-up visits. In the first trimester, chorion villus sampling was done at 11 weeks of gestation since both mother and father were carriers of beta thalassemia, and both co-twins were reported as being carrier and having normal constitutional karyotype.

The biometrics of the surviving fetus was compatible with 27 weeks of gestation, and 24x25 mm view compatible with hyperechogenic intraventricular hematoma on the frontal horn of (left upper) left lateral ventricle (**Fig. 1**) and heterogeneity on adjacent cerebral parenchyma were found. With these findings, fetal MRI was requested with the pre-diagnosis of



**Fig. 1.** Hyperechogenic view compatible with hemorrhage in frontal horn of the left lateral ventricle.

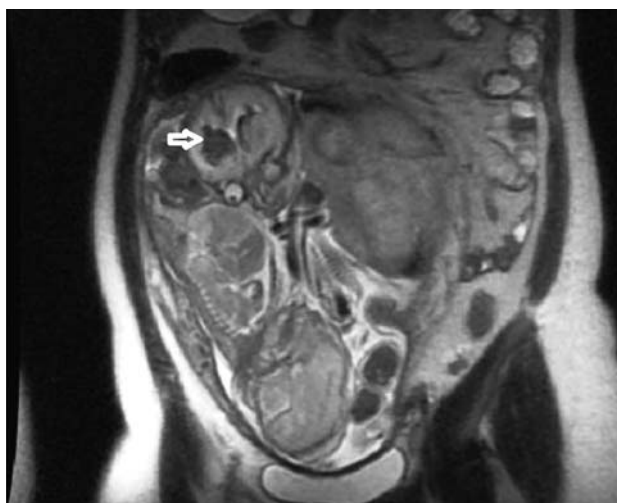


**Fig. 2.** Ventriculomegaly is seen in the control ultrasonography of the case.

grade 3 and higher intraventricular hemorrhage in the surviving fetus. In the MRI performed, hemorrhage indicators reaching to parenchyma and opening to ventricle were observed on bilateral basal ganglions, being more distinct on the left. As the ventricles were observed as wider, with these findings, the lesion was evaluated as grade IV germinal matrix hemorrhage (Figs. 2 and 3). In the ultrasonographic examination one week later, the lateral ventricle width was measured as about 18 mm bilaterally (Fig. 4), and in the third examination carried out at 29 weeks of gestation, it was understood that there was no progress in terms of sonographic findings compared to the previous evaluation. When the patient was pregnant for 29 weeks and 6 days, she referred with the complaints of contractions and rupture of membrane. The patient delivered 1153 g living fetus and 570 g macerated ex fetus by cesarean due to the previous cesarean history. Following the delivery, no pathological examination was carried out on the in utero exitus fetus due to the fact that it was macerated. In the transfontanelle ultrasonography of the case carried out at neonatal period, 11.5 x 12 mm heterogeneous echogenic regions adjacent to lateral horn pressuring on left lateral ventricular anterior horn and findings compatible with periventricular leukomalacia were observed, and their follow-ups are still continue.

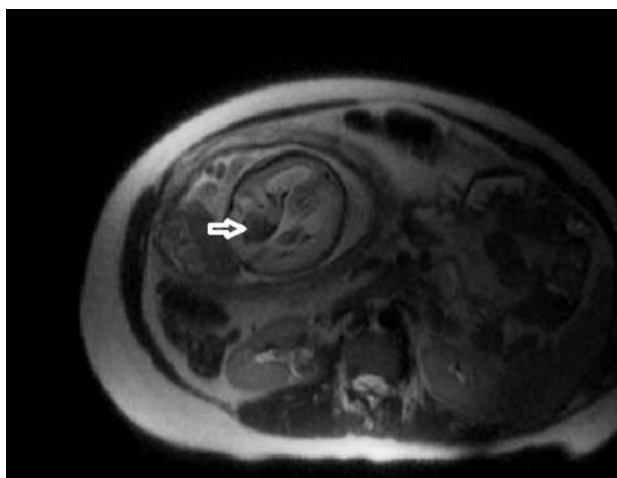
## Discussion

Death of a co-twin is seen in 5% of all twin pregnancies independent from chorionicity.<sup>[11]</sup> The determining factor in the problems faced by surviving co-twin after the death of a co-twin is chorionicity. When monochorionic and dichorionic twin pregnancies above 20 weeks of gestation are compared, the risk to lose one co-twin in a monochorionic twin pregnancy is 6 times higher than the same risk in a dichorionic twin pregnancy. Neurological sequel is seen at a rate of 18% in case of the death of a co-twin, and this rate is 1% in dichorionic ones.<sup>[9]</sup> In case of the death of a co-twin, ischemic lesions are seen in the surviving co-twin and they appear in sub-acute period in the ultrasonography.<sup>[1]</sup> Ventriculomegaly and hiperechogenic view associated with the bleeding in the ventricle may be presented at sub-acute and chronic periods by ultrasonography. Polymicrogyria, encephalomalacia, bleedings, germinolytic cysts, ventriculomegaly and delay of sul-



**Fig. 3.** In T2A examination, the findings (arrow) compatible with grade IV germinal matrix hemorrhage are seen at axial section.

cus formation are among the findings that may be observed in the central nervous system in case of the death of a co-twin.<sup>[10]</sup> It is difficult to present all of the findings above, especially those secondary to ischemia, in the ultrasonography. In cases with normal findings observed in the sonography, the findings secondary to ischemia may be detected at magnetic resonance imaging.<sup>[9]</sup> Ischemia is together with local or diffuse signal intensity increased at T2A cross-sections in germinal matrix, gray or white matter. In case of the death of a co-twin, the findings which cannot be presented by



**Fig. 4.** In T2A examination, the findings (arrow) compatible with grade IV germinal matrix hemorrhage are seen at coronal section.

ultrasonography but found in MRI such as polymicrogyria, encephalomalacia, germinolytic cysts, bleedings, delay of sulcus formation and ventriculomegaly appear in 1/3 of surviving co-twins.<sup>[12]</sup> Jelin et al.<sup>[13]</sup> found TTTS in 9 out of 21 monochorionic co-twins and they found abnormal MRI findings in 7 out of these 9 cases despite the normal ultrasonographic findings. Acute cerebral ischemia appears in hours (even minutes) following the death of a co-twin, and therefore, there is small amount of time to do anything in terms of patient management. Although diffusion-weighted MRI helps to present acute cerebral ischemia, most of the cases do not have such a chance due to late diagnosis. Diffusion-weighted cross-sections are open for fetal movements due to long procedure durations and associated movement artifacts.<sup>[10]</sup> Our case was being followed up with an interval of two weeks until the death of co-twin was detected. In the examination when the death of co-twin was detected, conservative model was chosen as the approach model after observing ventriculomegaly and suspected hemorrhage of frontal horn in the surviving co-twin. It was decided to monitor pregnancy and MRI was utilized for confirming the diagnosis. Although there is a limited number of publication reporting that intrauterine transfusion may be applied for fixing fetal anemia during acute period in monochorionic twin pregnancies where one of co-twins is lost, the results obtained are quite unsatisfactory.<sup>[14]</sup>

## Conclusion

In case of the death of co-twin, surviving co-twin should be evaluated by ultrasonographic findings first, then certainly by MRI if no finding is detected in the ultrasonography. In cases without any ultrasonography findings, MRI findings should be taken into consideration when providing consultancy to family by keeping in mind that non-existence of ultrasonography findings may be misleading. If imaging findings are not detected or be doubtful, magnetic resonance imaging should be repeated 2-3 weeks later in order to detect changes appearing on sub-acute and chronic periods.

**Conflicts of Interest:** No conflicts declared.

## References

1. Evans MI, Lau TK. Making decisions when no good choice exist: delivery of the survivor after intrauterine death of the co-twin in monochorionic twin pregnancies. *Fetal Diagn Ther* 2010;28:191-5.
2. Morokuma S, Tsukimori K, Anami A, Fukushima K, Morioka T, Wake N. Brain injury of the survivor diagnosed at 18 weeks of gestation after intrauterine demise of the co-twin: a case report. *Fetal Diagn Ther* 2008;23:146-8.
3. Kaufman HK, Hume RF, Calhoun BC, Carlson N, Yorke V, Elliot D, et al. Natural history of twin gestation complicated by in utero fetal demise: associations of chorionicity, prematurity and maternal morbidity. *Fetal Diagn Ther* 2003;18:442-6.
4. Bajoria R, Wee LY, Anwar S, Ward S. Outcome of twin pregnancies complicated by single intrauterine death in relation to vascular anatomy of the monochorionic placenta. *Hum Reprod* 1999;14:2124-30.
5. Okumura A, Hayakawa F, Kato T, Tsuji T, Negoro T, Watanabe K. Brain malformation of the surviving twin of intrauterine co-twin demise. *J Child Neurol* 2007;22:85-8.
6. Hillman SC, Morris RK, Killby MD. Co-twin prognosis after single uterine death: a systematic review and meta-analysis. *Obstet Gynecol* 2011;118:928-40.
7. Benirschke K. Intrauterine death of a twin: mechanisms, implications for surviving twin, and placental pathology. *Semin Diagn Pathol* 1993;10:222-31.
8. Bajoria R, Kingdom J. The case for routine determination of chorionicity and zygosity in multiple pregnancy. *Prenat Diagn* 1997;17:1207-25.
9. Ong SCC, Zamora J, Khan KS, Kilby MD. Prognosis for the co-twin following single twin death: systematic review. *BJOG* 2006;113:992-8.
10. Glenn OA, Coakley FV. MRI of the fetal central nervous system and body. *Clin Perinatol* 2009;36:273-300.
11. Kilby MD, Govind A, O'Brien PM. Outcome of twin pregnancies complicated by a single intrauterine death: a comparison with viable twin pregnancies. *Obstet Gynecol* 1994;84:107-9.
12. Simonazzi G, Segata M, Ghi T, Sandri F, Ancora G, Bernardi B, et al. Accurate neurosonographic prediction of brain injury in the surviving fetus after the death of a monochorionic twin. *Ultrasound Obstet Gynecol* 2006;27:517-21.
13. Jelin AC, Norton ME, Bartha AI, Fick AL, Glenn OA. Intracranial magnetic resonance imaging findings in the surviving fetus after spontaneous monochorionic cotwin demise. *Am J Obstet Gynecol* 2008;199:398.e1-e5.
14. Senat MV, Bernard JP, Loizeau S, Ville Y. Management of single fetal death in twin-to-twin transfusion syndrome: a role for fetal blood sampling. *Ultrasound Obstet Gynecol* 2002;20:360-3.