

# Spontaneous pneumomediastinum and pneumothorax developing after vaginal delivery

Ersin Çintesun<sup>1</sup>, Feyza Nur İncesu Çintesun<sup>2</sup>

<sup>1</sup>Department of Obstetrics and Gynecology, Faculty of Medicine, Selçuk University, Konya, Turkey

<sup>2</sup>Gynecology and Obstetrics Clinic, Konya Training and Research Hospital, Konya, Turkey

## Abstract

**Objective:** We aimed to present spontaneous pneumomediastinum and pneumothorax developing after vaginal delivery.

**Case:** Dyspnea and chest pain were observed in 18-year-old primigravida patient with 40 weeks of gestation 2 hours after vaginal delivery. She was examined with the suspicion of pulmonary embolism. After blood gas analysis, chest radiography and pulmonary CT scan, hypocarbia and air in mediastinum and pleura of the patient. The patient was established with the diagnosis of spontaneous pneumomediastinum and pneumothorax. She was monitored for two days with supportive care such as resting, oxygen treatment and antibiotherapy, and discharged with full recovery.

**Conclusion:** Spontaneous pneumomediastinum and pneumothorax after delivery are rare complications with mostly benign progress yet with fatal potential. Cases such as dyspnea, chest pain and subcutaneous emphysema should also be considered in differential diagnosis.

**Keywords:** Pneumothorax, pneumomediastinum, delivery.

## Özet: Vajinal doğum sonrası gelişen spontan pnömomediastinum ve pnömotoraks

**Amaç:** Vajinal doğum sonrası meydana gelen spontan pnömotoraks ve pnömomediastinum olgusunun sunulması amaçlanmıştır.

**Olgu:** Primigravid 40 haftalık gebeliği olan 18 yaşındaki hastada vajinal doğumdan iki saat sonra nefes darlığı ve göğüs ağrısı izlendi. Pulmoner emboli şüphesi ile hasta tetkik edildi. Kan gazı alınması, akciğer grafisi ve akciğer tomografisi çekilmesi sonucunda hastada hipokarbi, mediastende ve sağ plevrada hava izlendi. Hastaya spontan pnömotoraks ve pnömomediastinum tanısı kondu. İstirahat, oksijen tedavisi ve antibiyoterapi gibi destek tedavileriyle iki gün takip edildikten sonra şifa ile taburcu edildi.

**Sonuç:** Doğum sonrası spontan pnömomediastinum ve pnömotoraks ender görülen, çoğunlukla selim seyirli ancak yine de ölümcül potansiyeli olan bir komplikasyondur. Nefes darlığı, göğüs ağrısı, cilt altı amfizem gibi durumlar da ayırıcı tanıda göz önünde tutulmalıdır.

**Anahtar sözcükler:** Pnömotoraks, pnömomediastinum, doğum.

## Introduction

Spontaneous pneumomediastinum and pneumothorax are the reasons for rare chest pain and dyspnea developing during delivery. Subcutaneous emphysema may also be observed.<sup>[1]</sup> It was first defined by Louis Hamman in 1945.<sup>[2]</sup> It is therefore also known as Hamman's syndrome. It is a quite rare condition. Approximately 200 cases were reported in the world and its estimated incidence is 1/100,000.<sup>[3,4]</sup> Despite its terrifying clinical findings, it is mostly benign and self-limiting.<sup>[3,5]</sup> The most common symptom is chest pain. Dyspnea, coughing and

palpitation are the additional symptoms. The final diagnosis is established radiologically. Although the progress of the disease is mostly benign, it may be combined with severe diseases with higher morbidity and mortality such as pulmonary embolism, amniotic fluid embolism, myocardial infarction and aortic dissection. In this case report, we aimed to discuss the case of spontaneous pneumomediastinum and pneumothorax developed after vaginal delivery of a primigravida 18-year-old woman at 40 weeks of gestation and the diagnosis and treatment methods of such cases.

**Correspondence:** Ersin Çintesun, MD. Department of Obstetrics and Gynecology, Faculty of Medicine, Selçuk University, Konya, Turkey. e-mail: ersincintesun@gmail.com

**Received:** November 9, 2016; **Accepted:** December 12, 2016

**Please cite this article as:** Çintesun E, İncesu Çintesun FN. Spontaneous pneumomediastinum and pneumothorax developing after vaginal delivery. Perinatal Journal 2016;24(3):174–177.

©2016 Perinatal Medicine Foundation

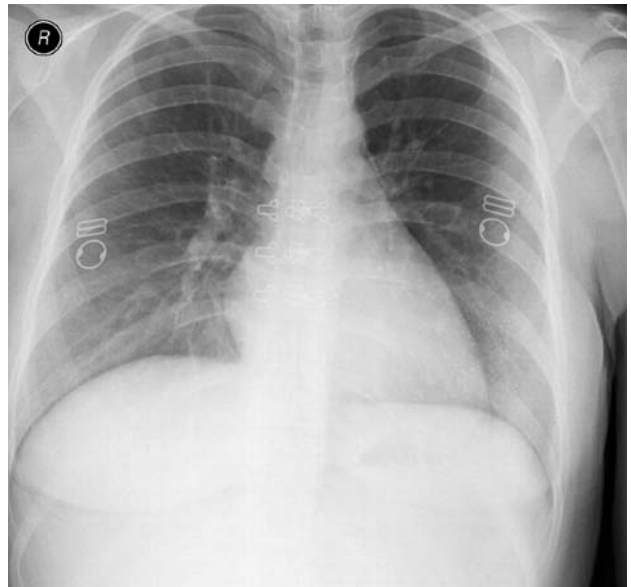
Available online at:  
www.perinataljournal.com/20160243006  
doi:10.2399/prn.16.0243006  
QR (Quick Response) Code:



deomed.

## Case Report

Eighteen-year-old primigravida woman at 40 weeks of gestation was hospitalized upon her pain complaints. It was observed in her vaginal examination that cervical opening was 2 cm and effacement was narrow. Upon the detection of contractions, she was taken to labor follow-up. In the ultrasonography, the baby was seen at vertex presentation. There was no abnormal finding in the systemic examination of the patient. She had no smoking history or any known lung disease. She did not have any additional disease or surgical history. According to her anamnesis, she had regular gestational follow-up visits and had normal follow-ups. After 6 hours following labor follow-up, she delivered 3550 g live female baby via mediolateral episiotomy. Kristeller maneuver was not performed during delivery. While no problem was detected during postpartum follow-ups of the patient, dyspnea and chest pain were observed in the postpartum second hour. No emphysema finding was found in chest and neck examination. Both lungs were participating in respiration equally, and lung and heart sounds were normal. No fluid or hematoma was observed in the abdomen during bedside abdominal ultrasonography. There was no swelling, temperature increase or rash in either leg. Arterial blood gas was collected from the patient and chest radiography was done (**Fig. 1**). Oxygen saturation was 90, blood pressure was 110/70 mm/Hg and the pulse was 95 per minute. It was found that the patient was tachypneic and respiratory rate was 28 per minute. Oxygen treatment was initiated as 4 l/m. Oxygen saturation was 95%,  $pO_2$  was 86 mmHg, and  $PCO_2$  was 20 mmHg. Electrocardiography (ECG) was performed. No pathological finding was found in ECG. The consultation of Chest Diseases Clinic was requested with the suspicion of pulmonary embolism. Since there was no distinct pathological finding in chest radiography and persistence of her complaints despite the oxygen therapy, thoracic CT scan was done upon the recommendation of the pulmonologist. Pneumomediastinum and pneumothorax were detected (**Fig. 2**). The patient was administered 100% oxygen therapy and prophylactic antibiotic treatment with 1st generation cephalosporin. Upon the regression of symptoms during the follow-ups, the patient was monitored via daily chest radiography at Thoracic Surgery Clinic, and she was discharged 2 days later with full recovery.



**Fig. 1.** Chest radiography.

## Discussion

While pneumomediastinum is defined as the presence of air in mediastinum, pneumothorax is defined as the collection of air in the pleural layers. It may develop spontaneously as well as depending on trauma, surgical intervention and pulmonary diseases.

Spontaneous pneumomediastinum is a rare complication of normal vaginal delivery. The disease mostly develops in the second phase of delivery in young, healthy and primigravida pregnant women. However, in our case, its findings were observed at postpartum second hour.

A few theories tried to explain the reasons of spontaneous pneumomediastinum. The most widely accepted theory is the marginal alveolar ruptured depending on the increased alveolar pressure due to the reasons such as potent and repeating Valsalva maneuver at second phase of delivery, vomiting and screaming.<sup>[6]</sup> Also, dissection of the sheath of vascular structures which cannot accommodate with increased alveolar pressure creates an airflow towards mediastinum, and the air collected in mediastinum moves to subcutaneous and retroperitoneal areas through fascial planes. Due to the settlement of airflow into the space between visceral and pleural peritoneum, pneumothorax may accompany.<sup>[7,8]</sup>

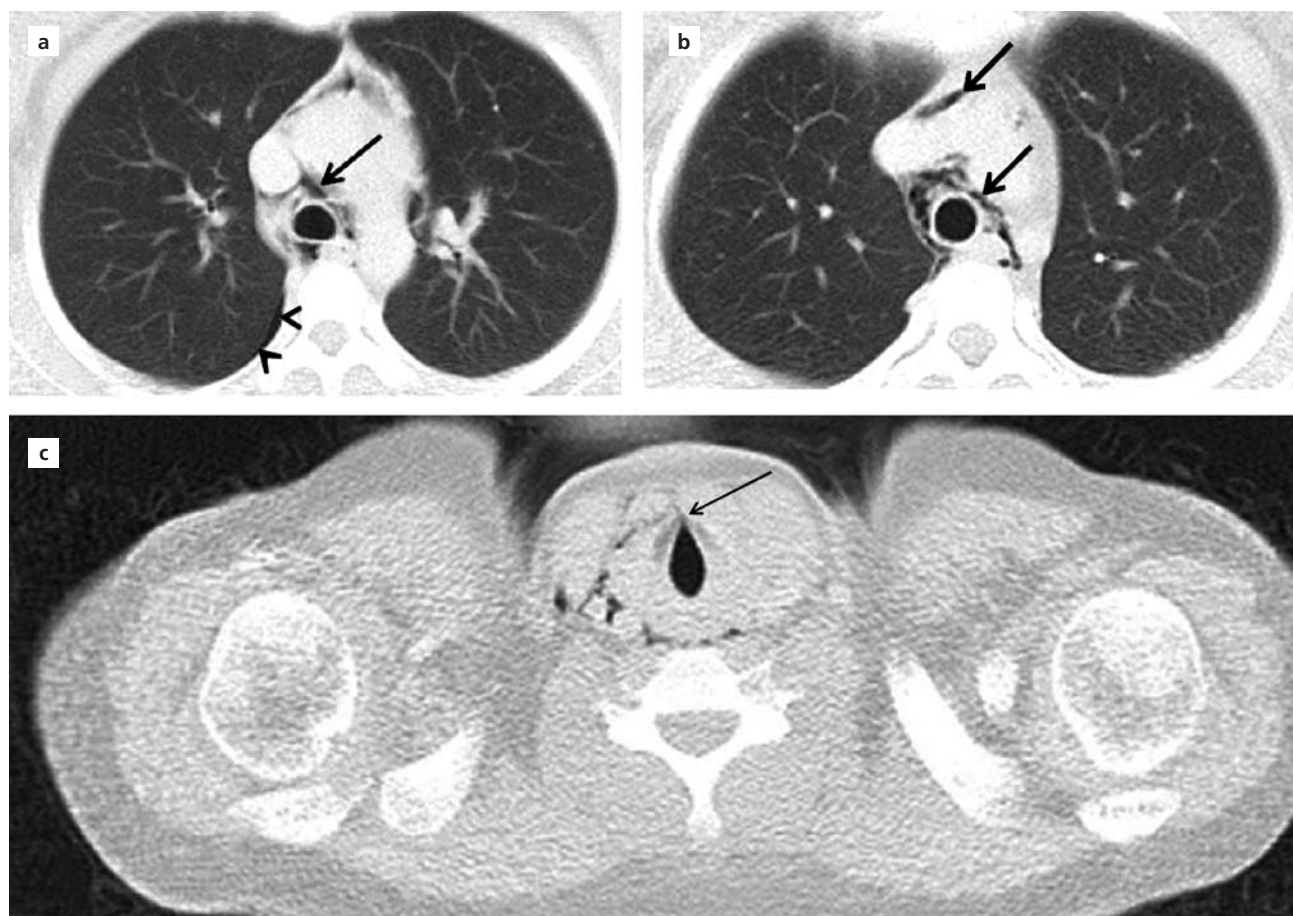
Chest pain as the most common symptom is followed by other symptoms such as coughing, dyspnea, palpitation, dysphagia, sensation of obstruction in throat and hoarseness. Feeling crackling in the neck region of the patient when palpating is also pathognomonic. The finding of typical physical examination is the sound of crackling on the anterior surface of chest, which is simultaneous with the cardiac peak time, during auscultation, also known as Hamman's sign.<sup>[6,7,9]</sup> Our case had chest pain and dyspnea. She had no subcutaneous emphysema.

Spontaneous pneumomediastinum should not be confused with pneumothorax, interstitial emphysema and pneumopericardium which require specific management. The diagnosis of spontaneous pneumomediastinum should be established as soon as possible, and tension pneumothorax which may pose a fatal threat for

patient, esophageal rupture, myocardial infarction, amniotic fluid embolism, pulmonary embolism and aortic dissection should certainly be considered in differential diagnosis.<sup>[10,11]</sup> We investigated our case by keeping pulmonary embolism in mind.

The primary diagnostic tool for spontaneous pneumomediastinum and pneumothorax is direct chest radiography. CT scan should be referred when chest radiography is insufficient or for the confirmation of other clinical diagnoses. CT scan shows both the less amount of air in mediastinum and the penetration of subcutaneous emphysema.<sup>[12]</sup> In our case, we did not observe any pathology in the chest radiography and we established the final diagnosis by CT scan.

Hamman's syndrome mostly has benign progress. The treatment for spontaneous pneumomediastinum is mostly analgesia, oxygen support and sedation. With



**Fig. 2.** (a) Arrow heads: pneumothorax, arrow: pneumomediastinum; (a-c) Arrows: pneumomediastinum.

support care, the clinical condition regresses mostly within 2 weeks. In our case, the clinical progress was benign and the patient did not require any interventional procedure.

The disease usually does not repeat and it was reported that follow-up is not needed.<sup>[13]</sup> However, even rarely, repeating cases were reported.<sup>[14]</sup>

## Conclusion

Spontaneous pneumomediastinum and pneumothorax are the conditions with fatal potential even they were self-limited in our case. In symptoms such as postpartum retrosternal pain and dyspnea, pneumothorax and pneumomediastinum should also be remembered in differential diagnosis.

**Conflicts of Interest:** No conflicts declared.

## References

1. Revicky V, Simpson P, Fraser D. Postpartum pneumomediastinum: an uncommon cause for chest pain. *Obstet Gynecol Int* 2010;2010:956142.
2. Hamman L. Mediastinal emphysema: the Frank Billings lecture. *JAMA* 1945;128:1–6.
3. Seidl JJ, Brotzman GL. Pneumomediastinum and subcutaneous emphysema following vaginal delivery: case report and review of the literature. *J Fam Pract* 1994;39:178–80.
4. Heffner J, Sahn S. Pleural disease in pregnancy. *Clin Chest Med* 1992;13:667–78.
5. Scala R, Madioni C, Manta C, Maggiorelli C, Maccari U, Ciarleglio G. Spontaneous pneumomediastinum in pregnancy: a case report. *Rev Port Pneumol* (2006) 2016;22:129–31.
6. Mahboob A, Eckford SD. Hamman's syndrome: an atypical cause of postpartum chest pain. *J Obstet Gynaecol* 2008;28:652–3.
7. Bonin MM. Hamman's syndrome (spontaneous pneumomediastinum) in a parturient: a case report. *J Obstet Gynaecol Can* 2006;28:128–31.
8. Tytherleigh MG, Connolly AA, Handa JL. Spontaneous pneumomediastinum. *J Accid Emerg Med* 1997;14:333–4.
9. Khurram D, Patel B, Farra MW. Hamman's syndrome: a rare cause of chest pain in a postpartum patient. *Case Rep Pulmonol* 2015;2015:201051.
10. Kandiah S, Iswariah H, Elgey S. Postpartum pneumomediastinum and subcutaneous emphysema: two case reports. *Case Rep Obstet Gynecol* 2013;2013:735154.
11. Sutherland FW, Ho SY, Campanella C. Pneumomediastinum during spontaneous vaginal delivery. *Ann Thorac Surg* 2002;73:314–5.
12. Kelly S, Hughes S, Nixon S, Paterson-Brown S. Spontaneous pneumomediastinum (Hamman's syndrome). *Surgeon* 2010;8:63–6.
13. Abolnik I, Lossos IS, Breuer R. Spontaneous pneumomediastinum: a report of 25 cases. *Chest* 1991;100:93–5.
14. Mohamed Faisal AH, Hazwani A, Soo CI, Andrea Ban YL. Recurrent spontaneous pneumothorax during pregnancy managed conservatively: a case report. *Med J Malaysia* 2016;71:93–5.