

# Treatment of an amniotic band syndrome with fetoscopic surgery: a case report

Selahattin Kumru<sup>1</sup> , Serdar Kaya<sup>2</sup> , Abdulkadir Atım<sup>3</sup> , Adnan Aslan<sup>4</sup> 

<sup>1</sup>Department of Obstetrics & Gynecology, Lara Anadolu Hospital, Antalya, Turkey

<sup>2</sup>Department of Maternal-Fetal Medicine, Istanbul Medipol University Hospital, Istanbul, Turkey

<sup>3</sup>Department of Anesthesiology & Reanimation, Lara Anadolu Hospital, Antalya, Turkey

<sup>4</sup>Department of Pediatric Surgery, Lara Anadolu Hospital, Antalya, Turkey

## Abstract

**Objective:** This study aimed to present an amniotic band syndrome case who underwent intrauterine fetoscopic surgery.

**Case:** On ultrasound examination, edema was detected at the distal of the right upper extremity. The constrictive amniotic band tangling around the extremity at the upper part of the right elbow and around the umbilical cord was detected during the fetoscopic examination. The amniotic band was released by using endoscopic scissors and grasper. It was observed that the right hand was at the flexion position and was able to return to the neutral position on neonatal examination.

**Conclusion:** Releasing amniotic band with fetoscopic surgery in amniotic band syndrome cases is an efficient method to prevent progressive destruction in the extremities and the procedure-related complications seem to be acceptable.

**Keywords:** Amniotic band syndrome, fetoscopic surgery, umbilical cord involvement.

## Introduction

Amniotic band syndrome is a relatively rare fetal congenital malformation associated with fibrous amniotic bands. While fibrous bands and constriction rings often involve the extremities, it may result in the deformation of several fetal structures.<sup>[1–4]</sup> The incidence is 1 per 1200–15,000 live births.<sup>[5]</sup> Although its etiology is not clearly known, various theories have been asserted so far. The intrinsic theory asserts that visceral defects develop in association with germinal disc malformation during early embryonic development.<sup>[6,7]</sup> Whereas, the extrinsic theory asserts that amnion rupture occurring during the early stages of pregnancy results in the development of fibrous bands. These bands lead to severe defects, even amputation, as a result of impaired blood circulation due to the constriction rings formed by adhering to or tangling around, particularly the extremities.<sup>[7,8]</sup> Amniotic

band syndrome may also develop as a result of amnion rupture associated with fetoscopic procedures and invasive procedures such as amniocentesis. There are differences in the literature in naming the condition such as “constriction band syndrome, constriction ring syndrome, or amniotic band sequence” because of the etiologic variations and wide range of defects.

Fetoscopic intervention is used for the treatment of cases with amniotic band syndrome. While laser coagulation is a successfully applied method for releasing the band, scissors and blunt dissection are also used.<sup>[9]</sup> An amniotic band syndrome case is presented who underwent intrauterine fetoscopic surgery.

## Case

A 23-year-old woman with gravida 2 and parity 1 had a history of revision curettage due to retained placenta

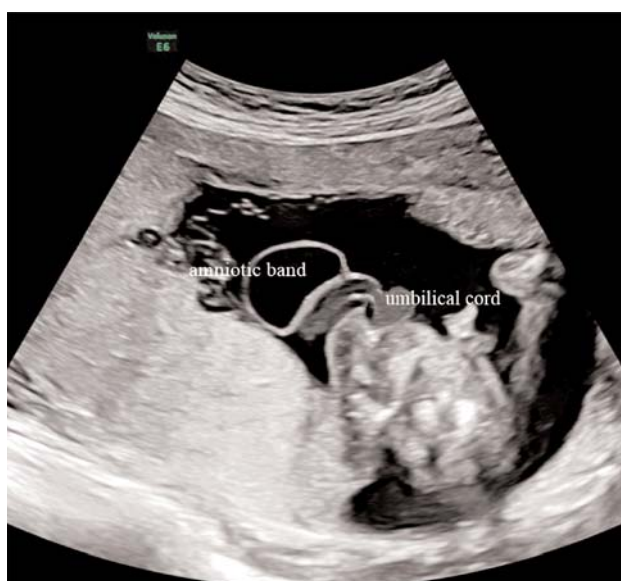**Correspondence:** Serdar Kaya, MD. Department of Maternal-Fetal Medicine, Istanbul Medipol University Hospital, Bahçelievler, Istanbul, Turkey.  
**e-mail:** kayaserdar75@hotmail.com / **Received:** March 1, 2022; **Accepted:** April 17, 2022

**How to cite this article:** Kumru S, Kaya S, Atım A, Aslan A. Treatment of an amniotic band syndrome with fetoscopic surgery: a case report. Perinat J 2022;30(2):195–199. doi:10.2399/prn.22.0302006

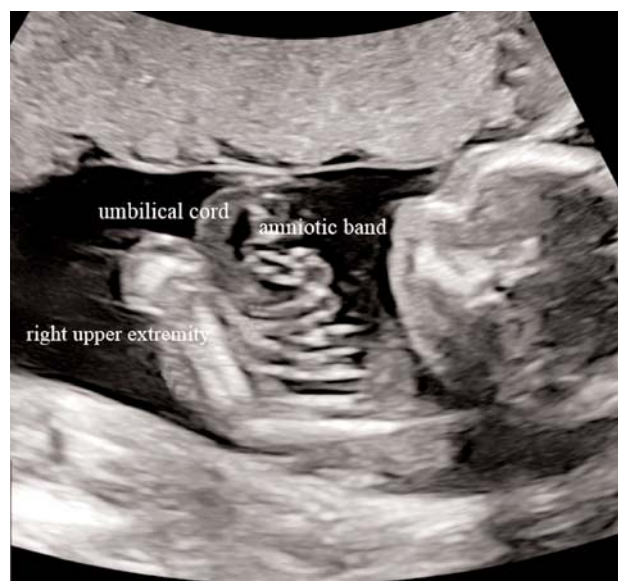**ORCID ID:** S. Kumru 0000-0001-6615-7666; S. Kaya 0000-0002-4092-7316; A. Atım 0000-0003-4501-5735; A. Aslan 0000-0002-4191-8606

after her first delivery. Ultrasonographic examination of the patient, who was pregnant for 15 weeks and 4 days by the last menstrual period (LMP), demonstrated that the placenta was fundal in location and the amniotic fluid volume was normal. An amniotic band was observed in close relation to the right upper extremity and the umbilical cord (**Fig. 1**). While the distal of the right upper extremity was edematous, there was a significant increase in the forearm diameter compared to the extremity on the other side (**Fig. 2**). While Doppler ultrasound showed blood flow in the left upper extremity, there was no blood flow at the distal of the right upper extremity. Blood flow of the umbilical cord was normal. With the preliminary diagnosis of amniotic band syndrome, the family was informed about the amniotic band syndrome, treatment options, and the related complications. After the counseling, the parents opted to have an intrauterine treatment. A 0.5 cm skin incision was made under spinal anesthesia, and a 3.3 mm curved surgical sheath (11540 KE, Karlz Storz, Tuttlingen, Germany) was advanced through the amniotic cavity under ultrasound guidance at 15 weeks and 6 days of gestation. It was observed that the amniotic band entangled the right upper extremity and the umbilical cord, and moreover a constrictive amniotic band

wrapped around the right upper extremity over the elbow. While the forearm and the hand at the distal of the constriction ring were edematous, hyperemia was observed at the proximal (**Fig. 3**). The wrapped portion of the amniotic band was cut using endoscopic scissors (26159 SHW, Karl Storz, Tuttlingen, Germany) and grasper (26159 UHW, Karl Storz, Tuttlingen, Germany). On fetoscopic view, the extremity was floating freely following the procedure, and the umbilical cord was released (**Supplementary material: S-Video 1**). The patient received tocolytic treatment and antibiotic prophylaxis before the procedure. On the postoperative second day, ultrasonographic examination showed the presence of distal blood flow at the right upper extremity and the reduction in the pre-operative edema. Furthermore, it was observed that the umbilical cord was freely floating in the amniotic cavity. The postoperative course was uneventful and the patient was discharged on the second day after the operation. Then, the patient was followed at two-week intervals. At 36 weeks of gestation, a 2300 g baby with Apgar score 5/10 was delivered via Cesarean section, with the indication of premature rupture of membrane and failed induction of labor. On neonatal examination, a skin lesion resulting from the constriction ring was found slightly over the elbow level



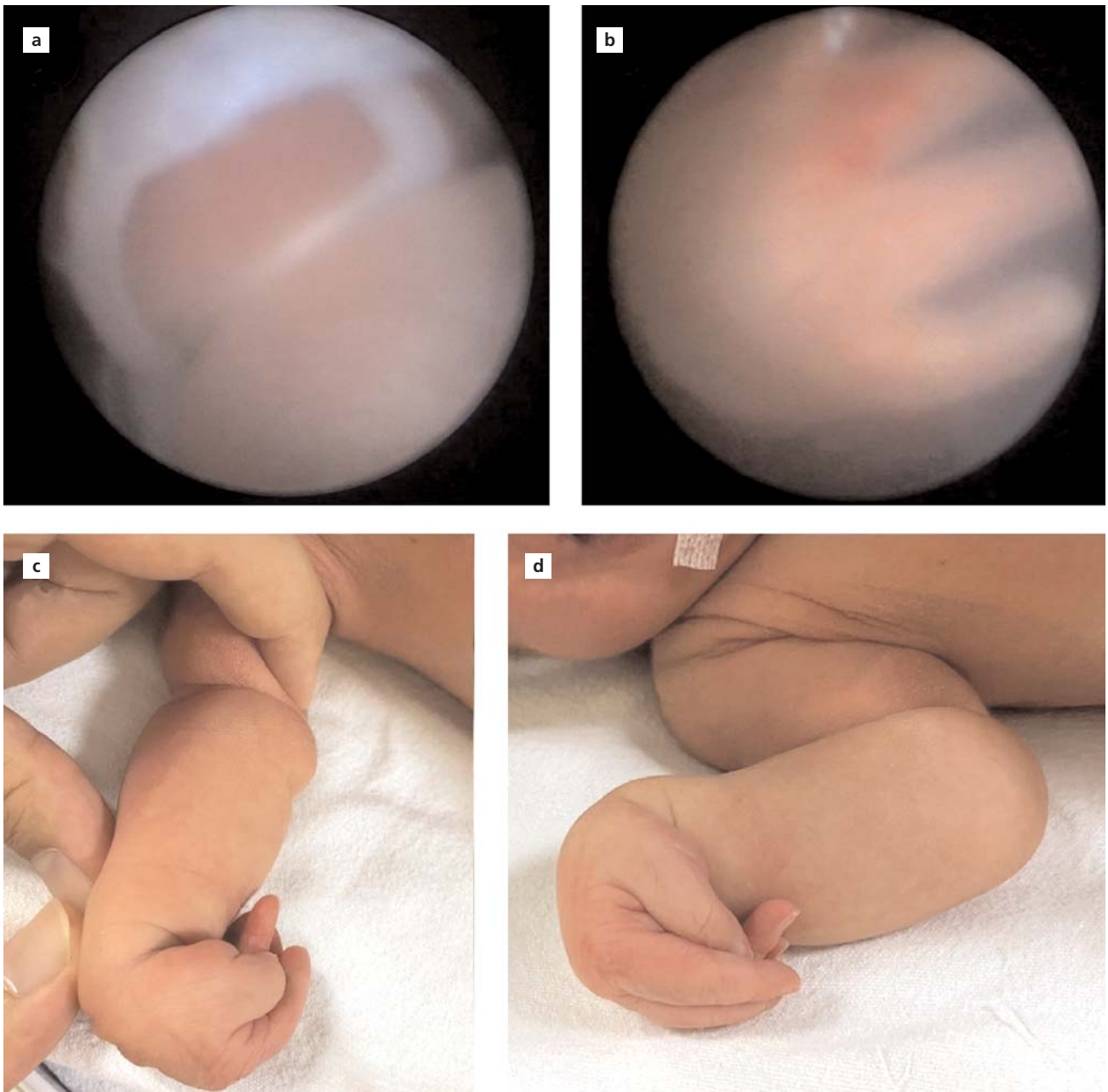
**Fig. 1.** An amniotic band was observed in close relation to the umbilical cord.



**Fig. 2.** The presence of an amniotic band in close relation to the edematous right upper extremity.

of the right upper extremity. There was no edema of the forearm and the hand, and the skin color and tonus were normal. However, the right hand was in a flexion position and could be rotated to the neutral position (**Fig. 3**). There was distal blood flow at the right upper extremity

as confirmed by color Doppler ultrasound examination of the upper extremity. While exercise and follow-up were recommended after neonatal examination by the orthopedic and plastic surgeon, surgical intervention was not found necessary.



**Fig. 3.** (a) Fetoscopic view of the constrictive ring wrapped around the right upper extremity over the elbow, and the edematous distal part of the extremity. (b) Fetoscopic view of the edematous hand. (c and d) Neonatal image of the right upper extremity.

## Discussion

The course of amniotic band syndrome may vary. It may regress spontaneously or result in dysfunction or amputation of the involved body compartment due to ischemia associated with edema and vascular obstruction.<sup>[10,11]</sup> While the prenatal diagnosis is made with ultrasonography, three-dimensional ultrasound and magnetic resonance imaging may additionally be useful during diagnostic workup. Fixed edematous fetal structures concomitant to the amniotic band forming constriction rings are the major signs of amniotic band syndrome. The complementary signs are edema at the distal of the involved organ and abnormal blood flow during Doppler ultrasound examination. It may result in the development of various malformations such as clubfoot, extremity amputation, abdominal wall defects, cleft lip and palate, and encephalocele, depending on the affected part of the body and severity of involvement.<sup>[9,12-14]</sup> In 57.1% of the amniotic band cases, ultrasonographic findings are consistent with the fetoscopic findings. In the remaining cases, additional findings including umbilical cord involvement are detected in the fetoscopic examination. Hand and feet involvements are present in 80% of all amniotic band cases.<sup>[12,13]</sup> Similarly, the amniotic band in this case tangled around the right upper extremity, and there was significant edema at the distal of right upper extremity involvement and abnormal Doppler ultrasound findings.

Several cases were diagnosed at early weeks of gestation and irreversible deformities developed within two weeks in high-risk cases.<sup>[15,16]</sup> However, since spontaneous regression was reported in the literature, close follow-up can be an appropriate option in selected cases.<sup>[10,12]</sup> Hüsler et al. have introduced a prenatal classification based on postnatal classification for amniotic band syndrome with involvement of extremities (**Table 1**). They have stated that the proposed classification could be useful while counseling parents on the risks and benefits of fetoscopic intervention. They also suggested that a favorable outcome is more likely in cases with abnormal Doppler flow where there is an arterial flow up to the distal extremity for intrauterine intervention (Grade 3A).<sup>[17]</sup> Gueneuc et al. have reported grade 3 patients as the eligible patient group for fetoscopic surgery.<sup>[9]</sup> However, patient selection criteria are not yet well-established for fetoscopic intervention. Indications for intervention in amniotic band syndrome cases have

**Table 1.** Prenatal classification of amniotic band syndrome involving the extremities.<sup>[17]</sup>

Stage 1	Amniotic bands without constriction
Stage 2	Constriction without vascular compromise
2a	Lymphedema; mild or absent
2b	Severe lymphedema
Stage 3	Severe constriction with progressive arterial compromise
3a	Abnormal distal Doppler studies
3b	No vascular flow to extremity
Stage 4	Bowing or fracture of long bones at constriction site
Stage 5	Intrauterine amputation

been extended to non-fatal conditions by means of the developments in fetoscopic procedures. It has been asserted that extremity function was preserved in 50% of the cases through intrauterine intervention.<sup>[12]</sup> While, umbilical cord involvement was reported in 10% of the cases diagnosed prenatally,<sup>[18]</sup> actual umbilical cord involvement confirmed during fetoscopy was reported in higher rates (80% of the cases). The umbilical cord can successfully be released with the fetoscopic intervention. Since umbilical cord involvement can be a life-threatening condition for the fetus, it is an eligible indication for intrauterine intervention.<sup>[19]</sup> In this case, besides an extremity involvement with abnormal Doppler findings (no blood flow at the distal extremity), it was found that the amniotic band tangled around the umbilical cord and thus was unable to move freely; however, the blood flow of the umbilical cord was normal. Umbilical cord involvement played a major role in counseling the parents, and making the decision for fetoscopic intervention together with the family and consequently, the umbilical cord was successfully released after the fetoscopic intervention.

Fetoscopic surgery is applied with success in cases of amniotic band syndrome; however, there are intervention-related complications such as intraamniotic hemorrhage, chorioamniotic separation, preterm premature rupture of membranes, preterm labor and fetal death.<sup>[9]</sup>

## Conclusion

Although there are limited case series in the literature, outcomes of fetoscopic surgery in amniotic band syndrome cases are promising. Releasing amniotic band can prevent progressive destruction in the extremities.



Developing case selection criteria for intervention, surgical experience and having more specialized centers will increase success rates.

**Funding:** This work did not receive any specific grant from funding agencies in the public, commercial, or not-for-profit sectors.

**Compliance with Ethical Standards:** The authors stated that the standards regarding research and publication ethics, the Personal Data Protection Law and the copyright regulations applicable to intellectual and artistic works are complied with and there is no conflict of interest.

## References

- Lowry RB, Bedard T, Sibbald B. The prevalence of amnion rupture sequence, limb body wall defects and body wall defects in Alberta 1980–2012 with a review of risk factors and familial cases. *Am J Med Genet A* 2017;173:299–308. [PubMed] [CrossRef]
- Walter JH Jr, Goss LR, Lazzara AT. Amniotic band syndrome. *J Foot Ankle Surg* 1998;37:325–33. [PubMed] [CrossRef]
- Eichhorn MG, Iacobucci JJ, Turfe Z. An unusual craniofacial cleft: amniotic band syndrome as a possible cause. *Int J Pediatr Otorhinolaryngol* 2015;79:616–9. [PubMed] [CrossRef]
- Seeds JW, Cefalo RC, Herbert WN. Amniotic band syndrome. *Am J Obstet Gynecol* 1982;144:243–8. [PubMed] [CrossRef]
- Garza A, Cordero JF, Mulinare J. Epidemiology of the early amnion rupture spectrum of defects. *Am J Dis Child* 1988;142:541–4. [PubMed] [CrossRef]
- Tanaka O, Koh T, Otani H. Amniogenic band anomalies in a fifth-month fetus and in a newborn from maternal oophorectomy during early pregnancy. *Teratology* 1986;33:187–93. [PubMed] [CrossRef]
- Koskimies E, Syvänen J, Nietosvaara Y, Mäkitie O, Pakkasjärvi N. Congenital constriction band syndrome with limb defects. *J Pediatr Orthop* 2015;35:100–3. [PubMed] [CrossRef]
- Torpin R. Amniochorionic mesoblastic fibrous strings and amniotic bands: associated constricting fetal malformations or fetal death. *Am J Obstet Gynecol* 1965;91:65–75. [PubMed] [CrossRef]
- Gueneuc A, Chalouhi GE, Boral D, Mediouni I, Stirnemann J, Ville Y. Fetoscopic release of amniotic bands causing limb constriction: case series and review of the literature. *Fetal Diagn Ther* 2019;46:246–56. [PubMed] [CrossRef]
- Pedersen TK, Thomsen SG. Spontaneous resolution of amniotic bands. *Ultrasound Obstet Gynecol* 2001;18:673–4. [PubMed] [CrossRef]
- Tadmor OP, Kreisberg GA, Achiron R, Porat S, Yagel S. Limb amputation in amniotic band syndrome: serial ultrasonographic and Doppler observations. *Ultrasound Obstet Gynecol* 1997;10:312–5. [PubMed] [CrossRef]
- Javadian P, Shamshirsaz AA, Haeri S, Ruano R, Ramin SM, Cass D, et al. Perinatal outcome after fetoscopic release of amniotic bands: a single-center experience and review of the literature. *Ultrasound Obstet Gynecol* 2013;42:449–55. [PubMed] [CrossRef]
- Goldfarb CA, Sathienkijkanchai A, Robin NH. Amniotic constriction band: a multidisciplinary assessment of etiology and clinical presentation. *J Bone Joint Surg Am* 2009;91 Suppl 4: 68–75. [PubMed] [CrossRef]
- Society for Maternal-Fetal Medicine; Gandhi M, Rac MWF, McKinney J. Amniotic band sequence. *Am J Obstet Gynecol* 2019;221:B5–B6. [PubMed] [CrossRef]
- Keswani SG, Johnson MP, Adzick NS, Hori S, Howell LJ, Wilson RD, et al. In utero limb salvage: fetoscopic release of amniotic bands for threatened limb amputation. *J Pediatr Surg* 2003;38:848–51. [PubMed] [CrossRef]
- Peiró JL, Carreras E, Soldado F, Sanchez-Duran MA, Aguirre M, Barber I, et al. Fetoscopic release of umbilical cord amniotic band in a human fetus. *Ultrasound Obstet Gynecol* 2009;33: 232–4. [PubMed] [CrossRef]
- Hüsler MR, Wilson RD, Horii SC, Bebbington MW, Adzick NS, Johnson MP. When is fetoscopic release of amniotic bands indicated? Review of outcome of cases treated in utero and selection criteria for fetal surgery. *Prenat Diagn* 2009;29: 457–63. [PubMed] [CrossRef]
- Heifetz SA. Strangulation of the umbilical cord by amniotic bands: report of 6 cases and literature review. *Pediatr Pathol* 1984;2:285–304. [PubMed] [CrossRef]
- Derderian SC, Iqbal CW, Goldstein R, Lee H, Hirose S. Fetoscopic approach to amniotic band syndrome. *J Pediatr Surg* 2014;49:359–62. [PubMed] [CrossRef]

**Supplementary material:** This article offers supplementary digital content which is available at [www.perinataljournal.com](http://www.perinataljournal.com)

This work is licensed under the Creative Commons Attribution-NonCommercial-NoDerivs 4.0 Unported (CC BY-NC-ND4.0) License. To view a copy of this license, visit <http://creativecommons.org/licenses/by-nc-nd/4.0/> or send a letter to Creative Commons, PO Box 1866, Mountain View, CA 94042, USA.

**Publisher's Note:** The content of this publication does not necessarily reflect the views or policies of the publisher, nor does any mention of trade names, commercial products, or organizations imply endorsement by the publisher. Scientific and legal responsibilities of published manuscript belong to their author(s). The publisher remains neutral with regard to jurisdictional claims in published maps and institutional affiliations.