

Prenatal Diagnosis and Management of a Case With Type-1 Congenital Cystic Adenomatoid Malformation

Mertihan Kurdođlu¹, İsmet Gün¹, Zeki Mesten², Ali Yılmaz³, Murat Muhçu¹, Ercüment Müngen¹

¹*Istanbul GATA Haydarpaşa Eğitim Hastanesi, Kadın Hastalıkları ve Doğum Kliniđi, İstanbul, Türkiye*

²*Gölcük Asker Hastanesi, Kadın Hastalıkları ve Doğum Kliniđi, Gölcük, Türkiye*

³*Çorlu Asker Hastanesi, Kadın Hastalıkları ve Doğum Kliniđi, Çorlu, Türkiye*

Abstract

Objective: To present a prenatally diagnosed case of type I congenital cystic adenomatoid malformation.

Case: A 13.9 X 10.8 mm unilocular and a 16.7 X 14.9 mm multilocular anechoic cystic structures at the left lung field with a marked mediastinal shift to the right were observed on ultrasonography of a fetus at 21 weeks and 3 days of gestation. With a tentative diagnosis of type I congenital cystic adenomatoid malformation, the pregnancy was followed with regular serial antenatal sonograms. After 35th weeks of gestation, the lesion started to reduce in size and the baby had a good prognosis after birth.

Conclusion: Unless hydrops fetalis or lifethreatening malformations coexist, a prenatally diagnosed isolated, type I congenital cystic adenomatoid malformation can be managed conservatively with a favorable prognosis.

Keywords: Congenital cystic adenomatoid malformation, prenatal diagnosis, management.

Tip-1 konjenital kistik adenomatoid malformasyonlu bir olgunun prenatal tanısı ve yönetimi

Amaç: Prenatal tanı almış bir tip I konjenital kistik adenomatoid malformasyon olgusunu sunmak.

Olgu: Bir fetüsün 21 hafta 3 günlük iken yapılan ultrasonografisinde, sol akciđer alanında sađa belirgin mediastinal yer deđiřtirmeye neden olan, 13.9 X 10.8 mm uniloküler ve 16.7 X 14.9 mm multiloküler anekoik kistik yapılar gözlemlendi. Tip I konjenital kistik adenomatoid malformasyon ön tanısıyla, düzenli seri antenatal sonogramlarla gebelik takibine devam edildi. Otuzbeřinci gebelik haftasından sonra lezyon küçülmeye başladı ve doğumdan sonra bebeđin prognozu iyiydi.

Sonuç: Hidrops fetalis veya hayatı tehdit edici malformasyonlar eşlik etmediđi sürece, prenatal tanı alan izole tip I konjenital kistik adenomatoid malformasyon olguları iyi bir prognoz beklentisiyle konservatif takip edilebilir.

Anahtar Sözcükler: Konjenital kistik adenomatoid malformasyon, prenatal tanı, yönetim.

Introduction

Congenital cystic adenomatoid malformation (CCAM) is a developmental hamartomatous abnormality of the lung and represents approximately 25% of all congenital lung lesions. As a distinct entity, it was firstly

described by Ch'in and Tang in 1949 and is characterized by overgrowth of the terminal bronchioles¹

The pathologic classification of CCAM is based on cyst size and includes three types.² Type I has 1 or more large (>2 cm) multiloculat-

ed cysts while type II has smaller uniform cysts (<1 cm). Type III is not grossly cystic and referred to as the "adenomatoid" type. During routine prenatal ultrasonography, CCAM is usually identified as a mass in the fetal chest which may be solid, cystic (solitary or multiple) or both. With large CCAMs, mediastinal shift, polyhydramnios, cardiac compression and fetal hydrops may also be found. The prognosis depends on the histologic type and is also influenced by the associated findings.

In this report, we aimed to present a case of large type I CCAM with mediastinal shift which was diagnosed prenatally at 21 weeks and 3 days of gestation and had a good prognosis after birth.

Case

A 29-year-old, gravida 1, para 0 woman was referred to our hospital for fetal evaluation following the identification of a large fetal thoracic cyst at 21 weeks and 3 days of gestation with a

presumptive diagnosis of diaphragmatic hernia. Before referral, the course of the pregnancy had been uneventful. We observed a 13.9 X 10.8 mm unilocular and a 16.7 X 14.9 mm multilocular anechoic cystic structures at the left lung field with a marked mediastinal shift to the right on B-mode imaging which was performed with a Voluson E8 Expert (GE Healthcare, Wauwatosa, WI, USA) ultrasound machine (Figure 1). The diaphragm was intact (Figure 2) and there were no hydrops fetalis or associated congenital anomalies. Amniocentesis was performed, which revealed a normal karyotype of 46, XY. The tentative diagnosis was type I congenital cystic adenomatoid malformation. After detailed counseling, the parents opted for continuation of the pregnancy. Regular serial antenatal sonograms revealed that the fetus had a persistent left lower lung cystic lesion until 35th weeks of gestation. Thereafter, it started to reduce in size and nearly 90% of it disappeared until delivery. A live male baby weighing 3170 g was delivered by cesarean section at 39 weeks

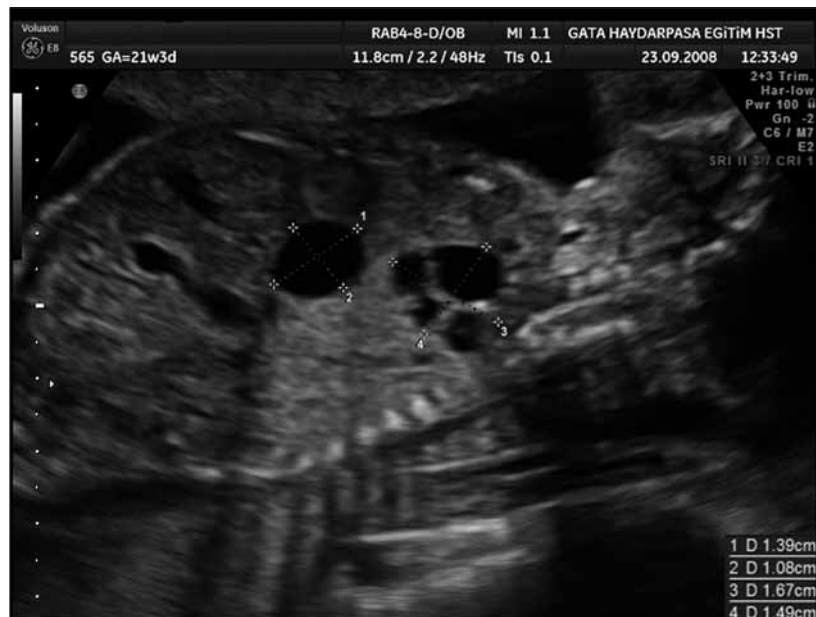

Figure 1. Shape 1. Sagittal ultrasonographic section of thorax in the fetus with type I congenital cystic adenomatoid malformation, showing cystic lesions in the left lung region.

and 5 days' gestation. Apgar scores were 9 at one minute and 10 at 5 minutes. The newborn breathed well and the signs of respiratory distress such as tachypnea, cyanosis, or dyspnea were not observed at birth. A magnetic resonance imaging (MRI) scan of the chest after birth revealed only a small remnant lesion of CCAM. Postnatal follow-up of the baby was uneventful until 7th month and the baby still receives regular follow-up.

Discussion

CCAM is believed to result from an arrest of normal fetal pulmonary maturation before the seventh week of gestation, leading to the development of dysplastic bronchopulmonary tissue.³ Approximately 4-26% of cases and mostly the ones with type II can be associated with other congenital abnormalities such as diaphragmatic hernia, skeletal malformations, extra lobar pulmonary sequestration, bilateral renal agenesis/dysgenesis, jejunal atresia, car-

diovascular malformation, pulmonary hypoplasia, depending on the time and type of insult. Syndactyly, lomber bifid spine and imperforation of the anus have also been shown in a case with type III.⁴ However, our case, CCAM type I, was not associated with any congenital anomalies.

Although ultrasonography is quite helpful in the prenatal diagnosis of CCAM, diagnostic errors are also possible. Mediastinal lesions, such as cystic teratoma or neurenteric cyst; diaphragmatic hernia, extralobar and intralobar bronchopulmonary sequestration and bronchogenic cyst should be considered in the differential diagnosis and excluded by careful ultrasonographic assessment with the help of color-flow Doppler.^{5,6} In our case, the patient was also referred to our clinic with a diagnosis of fetal diaphragmatic hernia and it was excluded by observing an intact diaphragm, normal stomach and abdominal anatomy.

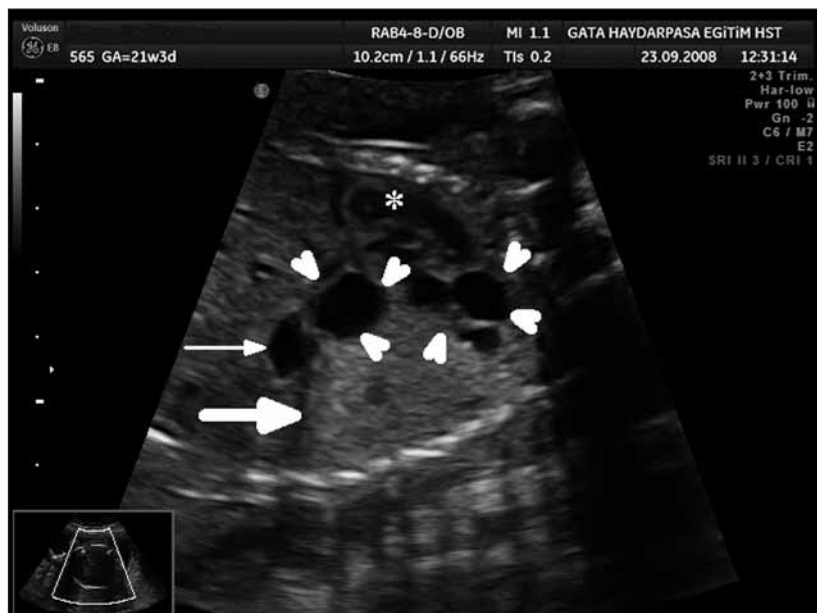


Figure 2. Shape 2. Sagittal ultrasonographic section of thorax and upper abdomen in the fetus with type I congenital cystic adenomatoid malformation, showing intact diaphragm (thick arrow), stomach (thin arrow), cystic lesions (arrowheads) in the left lung and heart (asterix).

There are conflicting opinions in the literature about the association of CCAM and chromosomal abnormalities. When a CCAM has been antenatally identified, although some authors advise to obtain a fetal karyotype only if there is an associated finding requiring chromosomal analysis,⁷ the others advise fetal and karyotyping in all cases of CCAM, because fetal prognosis has been improved in recent years with intrauterine and/or postpartum therapy in these pregnancies.⁸ More specifically, beside the reports indicating that CCAM Type II appears to be more frequently associated with other fetal abnormalities and aneuploidy,⁹ there is a case series not revealing any abnormal karyotype in a review of 18 CCAM patients (9 of them are CAM Type II).¹⁰ As proposed by International Society of Ultrasound in Obstetrics and Gynecology & Fetal Medicine Foundation,¹¹ our clinical approach is to offer fetal karyotyping when major defects are demonstrated on 18–23-week scan even if these defects are apparently isolated.

Most of the time, the lesions seen in CCAM are unilateral. However, very rarely, bilateral lesions may be encountered.⁴

Although it has not been encountered in other series, Sapin et al. observed the great predominance of left-sided lesions in their patients.¹² In our case, the lesion was unilateral and left-sided. According to the classification of CCAM using ultrasonographic findings, our case was CCAM type I and had a good prognosis. In general, this type is the most common form of CCAM and has the best prognosis of the three types, with a survival rate of 69%. Both of type II and type III have a poor prognosis (pulmonary and cardiac insufficiency in the newborn) with a mortality rate of 100%.^{2,13} Baytur et al. also reported a case with type I CCAM in which the prognosis was also good.¹⁴ Therefore, pregnancy termination may be advised when an extensive type II or type III

malformation is detected before viability is reached while referring the patient to a perinatal center for scheduling the delivery and providing optimum neonatal care should be considered if the anomaly is detected later and if the findings are type I.¹⁵ The prognosis is also considered to be worse if CCAM is microcystic (5 mm or less) and associated with a mediastinal shift, polyhydramnios or hydrops.¹⁵ In our case with type I CCAM, the lesion was not microcystic and the only associated finding was a mediastinal shift. The pregnancy was decided to go ahead and the prognosis of the baby was not poor. Therefore, in our opinion, the associated findings other than nonimmune hydrops fetalis or accompanying life-threatening malformations may not affect the clinical outcome of the patients significantly. In our case, gradual reduction in the size of the mass and shift of the mediastinum back to the midline was observed during the last trimester of pregnancy. Postnatal magnetic resonance imaging also confirmed the spontaneous regression of the lesion. The exact mechanism by which these lesions shrink is unclear. Although the natural history of prenatally diagnosed pulmonary lesions is variable, Adzick reported that approximately 15% of CCAM lesions may decrease in size during gestation.¹⁶ Therefore it is advised to follow-up these cases with serial prenatal sonograms and postnatal imaging studies.⁶

Conclusion

As a conclusion, after extensive counseling, a prenatally diagnosed isolated, CCAM can be managed conservatively with a favorable prognosis unless hydrops fetalis or life-threatening malformations coexist. Since the lesion might regress spontaneously, a serial scan should be arranged to monitor the size of the lesion in all affected fetuses.

References

1. Ch'In KY, Tang MY. Congenital adenomatoid malformation of one lobe of a lung with general anasarca. *Arch Pathol (Chic)* 1949; 48: 221-9.
2. Stocker JT, Madewell JE, Drake RM. Congenital cystic adenomatoid malformation of the lung. Classification and morphologic spectrum. *Hum Pathol* 1977; 8: 155-71.
3. Moerman P, Fryns JP, Vandenberghe K, Devlieger H, Lauweryns JM. Pathogenesis of congenital cystic adenomatoid malformation of the lung. *Histopathology* 1992; 21: 315-21.
4. Aksoy F, Ramazanoglu R, Ően C. Congenital Cystic Adenomatoid Malformation Type III Associated with Congenital. *Perinatology Journal* 2000; 8: 123-5.
5. Nuchtern JG, Harberg FJ. Congenital lung cysts. *Semin Pediatr Surg* 1994; 3: 233-43.
6. Winters WD, Effmann EL. Congenital masses of the lung: prenatal and postnatal imaging evaluation. *J Thorac Imaging* 2001; 16: 196-206.
7. Bianchi DW, Crombleholme TM, D'Alton ME. Cystic adenomatoid malformation. In: Bianchi DW, Crombleholme TM, D'Alton ME (Ed). *Fetology: Diagnosis and Management of the Fetal Patient*. New York: McGraw-Hill 2000; Chap. 37, pp. 289-298.
8. Roberts D, Sweeney E, Walkinshaw S. Congenital cystic adenomatoid malformation of the lung coexisting with recombinant chromosome 18. A case report. *Fetal Diagn Ther* 2001; 16: 65-7.
9. Nyberg DA, Mahony BS, Pretorius DH. *Diagnostic Ultrasound of Fetal Anomalies, Text and Atlas*. Chicago: Mosby-Year Book; 1990; p. 276-279, 712-715.
10. Dumez Y, Mandelbrot L, Radunovic N, Revillon Y, Dommergues M, Aubry MC et al. Prenatal management of congenital cystic adenomatoid malformation of the lung. *J Pediatr Surg* 1993; 28: 36-41.
11. Pilu G, Nicolaides K, Ximenes R, Jeanty P, (with the collaboration of Snijders R). Features of chromosomal defects. In: Pilu G, Nicolaides K, Ximenes R, Jeanty P (Ed). *Diagnosis of Fetal Abnormalities: The 18-23 Weeks Scan*. London, ISUOG & Fetal Medicine Foundation, 2002; Chap: 10.
12. Sapin E, Lejeune VV, Barbet JP, Carricaburu E, Lewin F, Baron JM et al. Congenital adenomatoid disease of the lung: prenatal diagnosis and perinatal management. *Pediatr Surg Int* 1997; 12: 126-9.
13. Merz E. Thoracic anomalies. In: Merz E (Ed). *Ultrasound in obstetrics and gynecology*. 2. Baskı. Stuttgart: Thieme; p. 2007; 262.
14. Baytur YB, Özçakır HT, Yüksel H, Genç AK, Çađlar H. Congenital Cystic Adematoid Malformation of the Lung Type 1. *Perinatology Journal* 2004; 12: 102-4.
15. Thorpe-Beeston JG, Nicolaides KH. Cystic adenomatoid malformation of the lung: prenatal diagnosis and outcome. *Prenat Diagn* 1994; 14: 677-88.
16. Adzick NS. Management of fetal lung lesions. *Clin Perinatol* 2009; 36: 363-76.