



Can a temporary isolated fetal megacystis during first trimester result in unexplained intrauterine fetal death at third trimester? A case report and review of the literature

Servet Haciveliöglu, Ayşenur Çakır Güngör, Meryem Gencer, Emine Coşar

Department of Obstetrics and Gynecology, Faculty of Medicine, Onsekiz Mart University, Çanakkale, Turkey

Abstract

Objective: In this study, we reported a case of a temporary isolated fetal megacystis presenting in the first trimester which resulted in intrauterine death of the fetus at term.

Case: A 26-year-old pregnant patient was referred to our clinic at her 12th gestational week for double test. The initial prenatal ultrasonography revealed an isolated megacystis measuring 11.2 mm longitudinally. Chorionic villus sampling was offered for fetal karyotyping but the patient did not accept. Afterwards, the megacystis regressed spontaneously at 14th gestational week. No other fetal anomaly was observed throughout gestation and the pregnancy went without any adverse problems. Sudden intrauterine fetal death was observed at 37th gestational week. The fetus was observed as normal macroscopically on postpartum examination and again fetal karyotyping could not be done due to rejection of the procedure by the family.

Conclusion: Contrary to our case, fetal karyotyping should be carried out in order to diagnose the etiology and to fulfill follow-up on fetus accurately whenever fetal megacystis is diagnosed during the first trimester.

Key words: Fetal megacystis, ultrasonography, fetal death.

Birinci trimesterde görülen geçici ve izole fetal megasistis üçüncü trimesterde açıklanamayan intrauterin fetal ölüme neden olabilir mi? Olgu sunumu ve literatür özeti

Amaç: Bu çalışmada, birinci trimesterde saptanan geçici ve izole fetal megasistis olgusunun miadında intrauterine fetal ölüme sonuçlanması gösterildi.

Olgu: Gebeliğinin 12. haftasında ikili test için kliniğimize yönlendirilen 26 yaşındaki hastanın ilk prenatal ultrason incelemesinde longitudinal çapı 11.2 mm olan fetal megasistis saptandı. Fetal karyotip tayini için koryon villus örnekleme önerilen hasta işlemi kabul etmedi. On dördüncü gebelik haftasında megasistis kendiliğinden geriledi. Gebelik boyunca başka fetal anomali izlenmedi ve gebelik normal seyretti. Gebeliğin 37. haftasında ani intrauterin fetal ölüm gerçekleşti. Doğum sonrası muayenede fetus makroskopik olarak tamamen normal değerlendirildi ve aile tarafından kabul edilmediği için fetal karyotipleme yapılmadı.

Sonuç: Sunduğumuz olgunun tersine, ilk trimesterde fetal megasistis saptanan hastalarda, hastalığın teşhisini ve gebeliğin takibini doğru yapmak için mutlaka fetal karyotipleme yapılmalıdır.

Anahtar sözcükler: Fetal megasistis, ultrasonografi, fetal ölüm.

Introduction

Fetal megacystis is defined as the abnormal distention of fetal bladder at any gestational week. Fetal bladder with 7 mm (and above) longitudinal diameter at first

trimester (10 to 14 weeks) is known as megacystis (mega bladder).^[1] The incidence rate during these gestational weeks is reported as approximately 1/1,600 among normal population.^[2] While megacystis is most-

Correspondence: Servet Haciveliöglu, MD. Çanakkale Onsekiz Mart Üniversitesi Tıp Fakültesi Hastanesi Kadın Hastalıkları ve Doğum ABD, Kepez, Çanakkale, Turkey.
e-mail: servetozden@comu.edu.tr

Received: June 23, 2012; **Accepted:** August 15, 2012

Available online at:
www.perinataljournal.com/20120202006
doi:10.2399/prn.12.0201006
QR (Quick Response) Code:



ly a temporary condition and does not have any clinical significance, it may be the early indication of severe lower urinary system anomalies in small patient groups accompanied by progressive indications. These anomalies are urethral atresia,^[3] posterior urethral valve,^[4] megalourethra,^[5] prune belly syndrome^[6] and megacystis-microcolon-intestinal hypoperistaltism syndrome.^[7]

Although fetal karyotyping is recommended when fetal megacystis is seen on first trimester, not all families allow for chorionic villus sampling (CVS) or amniocentesis on second trimester. Therefore, it is needed to follow-up pregnancy without the result of fetal karyotyping in some cases. However, there is no sufficient data in the literature about the prognosis of cases who do not have any karyotyping results. At this point, believing that it would contribute to the literature, we reported a case of a temporary isolated fetal megacystis in the first trimester with unknown fetal karyotyping, displayed a spontaneous regression on bladder size and resulted in unexplained intrauterine death of the fetus at term.

Case Report

No characteristic was detected in the backgrounds of 26-year-old patient and her family who had a 12-week-and-4-day baby (G1P0) according to her last menstrual period. In the obstetric ultrasonography, crown-rump length (CRL) was measured as 57.9 mm (12 weeks and 2 days) (Figure 1) and nuchal translucency (NT) was

measured as 1.6 mm (Figure 2). While “a wave” was monitored on ductus venosus, tricuspid regurgitation (TR) was not monitored. Nasal bone was normal and fetal heart rate was 145 bpm. No fetal disorder was detected except fetal megacystis. Follow-up by weekly ultrasonography was recommended to the patient who did not accept chorionic villus sampling for fetal karyotyping analysis. Bladder was observed completely normal on ultrasonographic examination performed on 14th week. No abnormal indication was found in the detailed fetal anatomic scan performed on 18th-20th week. Bladder, kidney and amniotic fluid were evaluated as normal. Unexplained intrauterine fetal death was observed on 37th week of the pregnant who had normal fetal development throughout the pregnancy, normal levels of fetal well-being tests and no obstetric complication development. After labor induction by oxytocin, male baby weighing 3,060 gram was delivered vaginally. No apparent anomaly was observed in the postpartum examination. Since family did not accept, fetal karyotype analysis and autopsy were not performed after delivery.

Discussion

The patient who had fetal megacystis with 11.2 mm longitudinal diameter at 12th gestational week did not accept recommended CVS and resulted in unexplained sudden intrauterine fetal death at 37th week where megacystis regressed spontaneously at 14th week was presented in this case report.

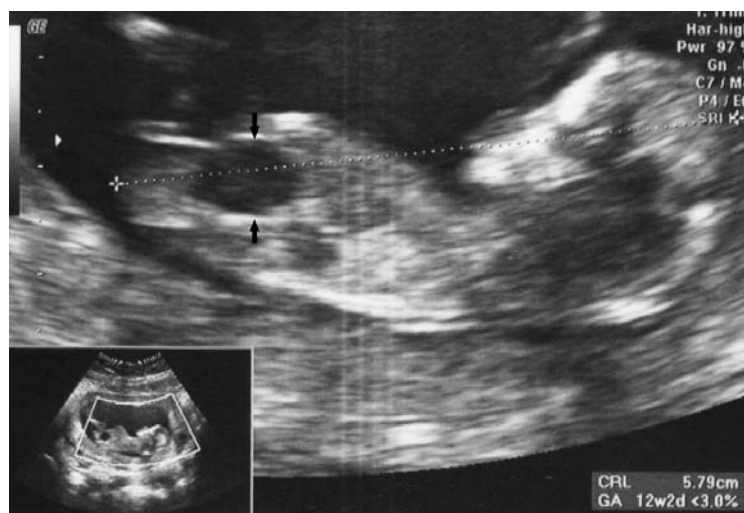


Figure 1. Views of fetal CRL (12 weeks and 2 days) and fetal megacystis (arrows).

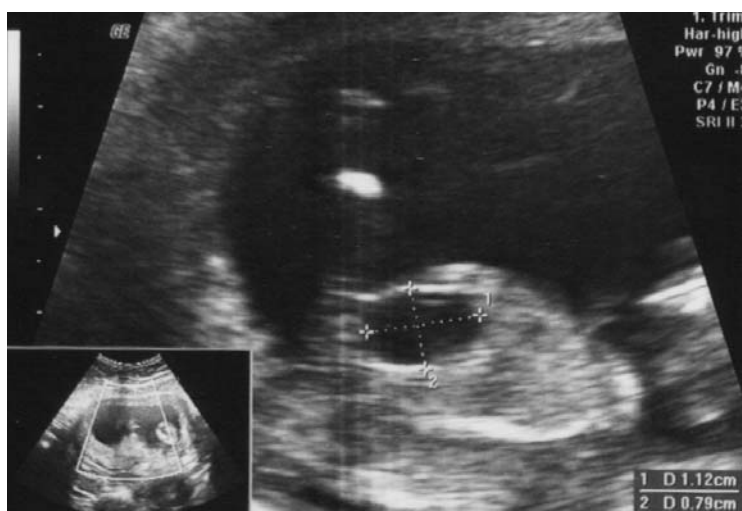

Figure 2. Fetal megacystis: two dimensions of fetal bladder.

It was found in the study performed by Gilpin et al.^[8] that bladder muscle fibers and autonomic innervation completely developed only when CRL was 77 mm (13.5th week). In the light of this study, this temporary distention of bladder can be explained by the development of a temporary function disorder arising during bladder development. Although it can be the indicator of fetal aneuploidies, the prognosis of fetal megacystis found on first trimester is usually good in most of pregnant women who have normal karyotype. In a retrospective study examining 145 fetuses with fetal megacystis on 10th-14th gestational weeks, 25% of fetuses with 7-15 mm longitudinal diameter of bladder (most frequent trisomy 13 and 18) and 10% of fetuses with more than 15 mm longitudinal diameter of bladder had chromosomal anomaly.^[9] In 90% of fetuses with 7-15 mm bladder diameter and without chromosomal anomaly, spontaneous regression was found in bladder sizes and no negative outcome related with urinary system was found during pregnancy.^[9]

In the prospective study of Kagan et al.^[2] including almost 57,000 cases of first trimester scans, they found 35 megacystis cases (1: 1,632) who were on their 11th-13th gestational weeks. In 31% of these 35 fetuses, chromosomal anomalies were found as trisomy 13 (54.5%), trisomy 18 (36.4%), and trisomy 21 (9.1%). Authors reported that bladder sizes recovered spontaneously until 16th gestational week in 90% of fetuses which had 7-15 mm longitudinal diameter of bladder and these fetuses were born healthily.

In the light of studies mentioned above, while there are data in the literature about the prognosis of cases with megacystis who had normal fetal karyotype, as in this case, chromosomal anomaly rate and fetal prognosis are not known in isolated megacystis cases which has unknown fetal karyotype and display spontaneous regression. Termination of pregnancies having fetal chromosomal anomaly without detecting the presence of regression in bladder sizes prevented us to get information about the prognosis of these fetuses. In another study,^[10] authors who found trisomy 21 on temporary and isolated fetal megacystis on pregnancies at 12th week emphasized that megacystis regressing spontaneously should not be used as a determinant to exclude Down syndrome. Generally, as the sizes of megacystis are on light limits (7-15 mm), so the regression possibility is higher. Sebire et al.^[11] found chromosomal anomaly in 3 of 15 fetal megacystis cases revealed on 10th-14th gestational week. In 7 of other 12 cases with normal chromosomes, bladder sizes recovered spontaneously until 20th week and fetal bladder was found between 8 and 12 mm in all pregnancies with spontaneous regression. Authors reported that all cases delivered healthy babies and only one case had mild Hydronephrosis. These findings of the authors are similar to those of Kagan et al.^[2] and Liao et al.^[9] In our case, 11.2 mm bladder diameter and spontaneous regression of megacystis at 14th gestational week is consistent with the literature.

Aneuploidy rates and prognoses of cases found to have megacystis as isolated on first trimester are not known exactly. When the literature is analyzed, it is not clear whether the megacystis in the studies performed is isolated or not.^[1,2,9] In a prospective study performed on 16 cases found to have fetal megacystis on 11th-15th gestational week, no chromosomal anomaly was found in cases although six fetuses had isolated megacystis. Authors suggested performing fetal karyotyping if especially additional anomalies exist in pregnancies found to have megacystis in the first trimester. In the light of findings of the authors, it can be considered that it is less likely there is a relationship between fetal aneuploidy and temporary and isolated fetal megacystis in our case. However, a final decision should not be made before performing karyotype analysis. It has been revealed by several studies that spontaneous abortion and early intrauterine losses are more in fetuses with first trimester megacystis.^[1,11] As in our case, first and third trimester intrauterine death rates are not known exactly yet.

Conclusion

Consequently, bladder sizes regress in following weeks in most of the fetuses with normal karyotype. In the literature, it is not known exactly whether intrauterine fetal death observed in third trimester has a relation with isolated and temporary fetal megacystis observed in first trimester or not. On the other hand, pathologies (including structural, chromosomal and genetic anomalies) not observed in the ultrasonography in pregnancies found to have fetal megacystis in first trimester may cause unexplained intrauterine fetal death in following gestational weeks. Therefore, it is important to determine fetal prognosis in pregnancies found to have fetal megacystis in first trimester and to do fetal karyotyping in order to help exact diagnosis and it should be recommended for all cases.

Conflicts of Interest: No conflicts declared.

References

1. Sebire NJ, Von Kaisenberg C, Rubio C, Snijders RJ, Nicolaides KH. Fetal megacystis at 10-14 weeks of gestation. *Ultrasound Obstet Gynecol* 1996;8:387-90.
2. Kagan KO, Staboulidou I, Syngelaki A, Cruz J, Nicolaides KH. The 11-13-week scan: diagnosis and outcome of holoprosencephaly, exomphalos and megacystis. *Ultrasound Obstet Gynecol* 2010;36:10-4.
3. Robyr R, Benachi A, Daikha-Dahmane F, Martinovich J, Dumez Y, Ville Y. Correlation between ultrasound and anatomical findings in fetuses with lower urinary tract obstruction in the first half of pregnancy. *Ultrasound Obstet Gynecol* 2005;25:478-82.
4. Matsui F, Shimada K, Matsumoto F, Obara T. Prenatal resolution of megacystis possibly caused by spontaneous rupture of posterior urethral valves. *J Pediatr Surg* 2008;43:2285-7.
5. Nijagal A, Sydorak RM, Feldstein VA, Hirose S, Albanese CT. Spontaneous resolution of prenatal megalourethra. *J Pediatr Surg* 2004;39:1421-3.
6. Favre R, Kohler M, Gasser B, Muller F, Nisand I. Early fetal megacystis between 11 and 15 weeks of gestation. *Ultrasound Obstet Gynecol* 1999;14:402-6.
7. Farrell SA. Intrauterine death in megacystis-microcolon-intestinal hypoperistalsis syndrome. *J Med Genet* 1988;25:350-1.
8. Gilpin SA, Gosling JA. Smooth muscle in the wall of the developing human urinary bladder and urethra. *J Anat* 1983;137:503-12.
9. Liao AW, Sebire NJ, Geerts L, Cicero S, Nicolaides KH. Megacystis at 10-14 weeks of gestation: chromosomal defects and outcome according to bladder length. *Ultrasound Obstet Gynecol* 2003;21:338-41.
10. Maymon R, Schneider D, Reish O, Herman A. First trimester spontaneous resolution of megacystis in a Down syndrome fetus. *Prenat Diagn* 2001;21:790-1.
11. Jouannic JM, Hyett JA, Pandya PP, Gulbis B, Rodeck CH, Jauniaux E. Perinatal outcome in fetuses with megacystis in the first half of pregnancy. *Prenat Diagn* 2003;23:340-4.