



Round ligament varicosities mimicking inguinal hernia in pregnancy: a case report

Esin Derin Çiçek, İsmail Yardımcıoğlu

Department of Radiology, Fatih Sultan Mehmet Training and Research Hospital, Istanbul, Turkey

Abstract

Objective: Round ligament varicosity is a condition which can be seen in patients who applied with the complaint of inguinal pain and/or inguinal mass during pregnancy and can be clinically confused with inguinal hernia in particular. Since its differentiation from other inguinal masses which may require surgical intervention is important, we present the diagnostic information and postpartum follow-up ultrasonographic findings of the case.

Case: We found venous vascular pattern after performing B-mode superficial ultrasonography and Doppler ultrasonography on the pregnant case, who applied with the complaint of painful inguinal mass and referred to our clinic with the pre-diagnosis of inguinal hernia, and we established the diagnosis of round ligament varicosity. Then, conservative approach was adapted and the pregnancy was completed without any problem. The varicosities regressed spontaneously after the delivery and disappeared completely.

Conclusion: It is possible to establish the diagnosis of round ligament varicosity radiologically, and it is recommended to perform ultrasonography and Doppler ultrasonography in pregnant cases who apply with the complaint of inguinal mass.

Keywords: Round ligament, inguinal canal, varicosity.

Özet: Gebelikte inguinal herniyi taklit eden round ligament varisleri: Olgu sunumu

Amaç: Round ligament variközitesi, gebelik esnasında kasık ağrısı ve/veya kasıkta şişlik şikayetiyle başvuran hastalarda görülebilen ve özellikle de klinik olarak inguinal fıtıklarla karıştırılabilecek bir durumdur. Cerrahi gerektirebilen diğer inguinal kitlelerden ayrımının önemli olması nedeniyle, olgunun tanı özelliklerini ve doğum sonrası kontrol ultrasonografi bulgularını sunmaktayız.

Olgu: Kasıkta ağrılı şişlik şikayeti ile başvuran ve inguinal herni ön tanısı ile kliniğimize gönderilen 3. trimesterdeki gebe olguya yapılan B-mod yüzeysel ultrasonografi ve Doppler ultrasonografi inceleme sonucunda, venöz vasküler patern tespit edildi ve round ligament varisi tanısı kondu. Bunun üzerine olguya konservatif yaklaşılarak ve gebelik problemsiz olarak tamamlandı. Varisler doğum sonrasında spontan olarak geriledi ve tamamen kayboldu.

Sonuç: Round ligament variközitesi tanısını radyolojik olarak koy-mak mümkün olup inguinal şişlik şikayeti ile gelen gebelerde ultrasonografi ve Doppler ultrasonografi inceleme yapılması önerilir.

Anahtar sözcükler: Round ligament, inguinal kanal, varis.

Introduction

Inguinal masses during pregnancy are not frequent conditions that we observe, and it is first suspected to be previously known or new inguinal hernia. Other differential diagnoses for inguinal mass lesions can be lymphadenopathy, cyst of the canal of Nuck, cystic lymphangioma, mesothelial cyst, round ligament varicosities, pseudoaneurysm, lipoma, endometriosis or abscess.^[1] We present our case with round ligament varicosity (RLV), which is one of the significant reasons of inguinal mass during pregnancy and reported in the literature rarely, in order to highlight that it can be easily diagnosed radiologically.

Correspondence: İsmail Yardımcıoğlu, MD. Department of Radiology, Fatih Sultan Mehmet Training and Research Hospital, Istanbul, Turkey. e-mail: ismailyardimcioglu@gmail.com

Received: March 23, 2017; **Accepted:** May 7, 2017

Please cite this article as: Derin Çiçek E, Yardımcıoğlu İ. Round ligament varicosities mimicking inguinal hernia in pregnancy: a case report. Perinatal Journal 2017;25(2):82-84.

©2017 Perinatal Medicine Foundation

Available online at:
www.perinataljournal.com/20170252001
doi:10.2399/prn.17.0252001
QR (Quick Response) Code:



Case Report

Thirty-one-year-old female patient, who was referred to our clinic for ultrasonographic examination at 29 weeks of gestation with the clinical suspicion of inguinal hernia, had a mass complaint which started with inguinal pain at 27 week of gestation and increased gradually. There were visible mass which was about 1.5–2 cm on the right groin and a slight sensitivity with probe pressure in the case whose first pregnancy was terminated with twin abortion and other pregnancy was completed with a problem-free singleton and who had no such complaints in her previous pregnancies.

In the superficial gray scale ultrasonography, a great number of anechoic structures were seen which had tubular and round shapes reaching up to 5.1 mm diameter on right inguinal area and which could be compressed with probe pressure (**Fig. 1**). In the colored Doppler ultrasonographic examination, venous drainage samples were collected and it was understood that they were dilated venous vascular structures (**Fig. 2**). Inguinal canal dilated to a diameter of 8.4 mm (**Fig. 3**). No other mass lesion or herniated bowel loop was observed during the examination.

Upon this diagnosis, the patient was taken to untreated follow-up during her pregnancy. On second-month ultrasonographic examination after the delivery, it was seen that the varicosities were regressed completely.

Discussion

Round ligament (ligamentum teres uteri), is the ligament that provides the uterine anteversion. Beside the pregnancy, cardinal ligament supports the uterine angle.

Round ligament starts from the lateral side of uterine, passes through inguinal canal and ends on labium majus.^[2] RLV, on the other hand, stems from round ligament veins and the inguinal canal which drains into inferior epigastric vein.^[2] Actual incidence of RLV is unknown, because there is limited number of cases reported in the literature. Although it is unavailable during the first pregnancy, it may appear in the following pregnancies of multiparous cases.^[1,2]

Round ligament varicosities are rarely seen at times other than during pregnancy.^[2] Pelvic veins dilate during pregnancy and they sometimes reach up to round

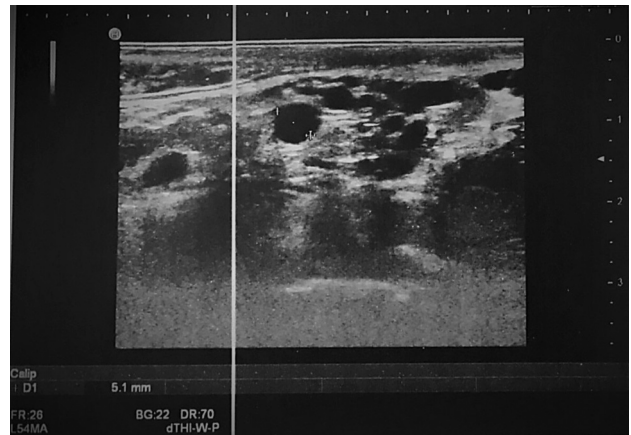


Fig. 1. Multiple serpiginous lesions with anechoic view and tubular and round shapes were found in gray scale ultrasonographic examination.

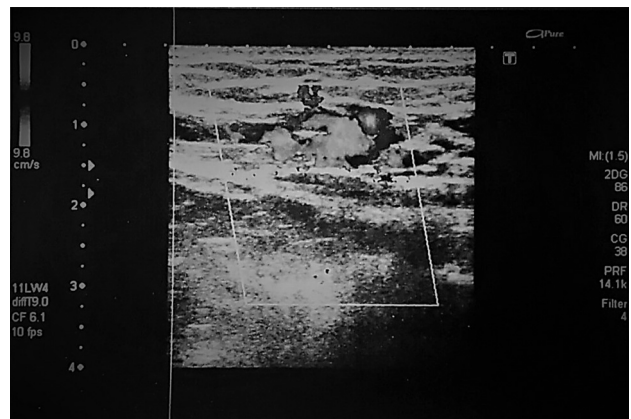


Fig. 2. In Doppler ultrasonographic examination, it was seen that cystic lesions were filled with colors. Venous flow with low output was found in spectral samples.

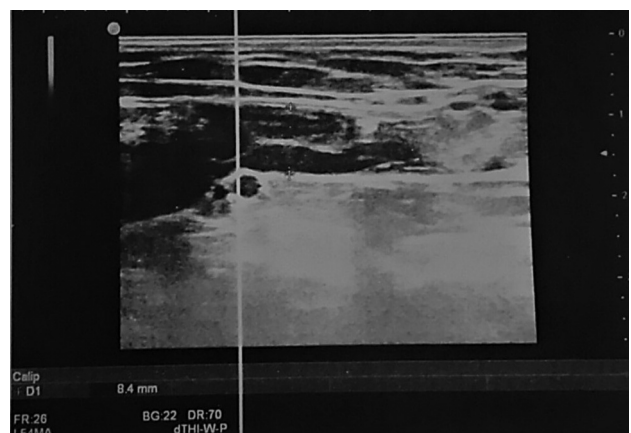

Fig. 3. Varicose veins reaching towards inguinal canal and dilatation in the inguinal canal at this level are seen.

ligament veins which pass through inguinal canal. The pressure of growing uterine on pelvic veins and the increase of cardiac output - venous return have an influential function.^[3-5] Also, progesterone receptors are within the round ligament veins and increasing progesterone level during pregnancy leads to the relaxation and dilatation of smooth muscles in these veins.^[6] In addition, inguinal hernia may also develop as a result of increased intraabdominal pressure during pregnancy. Both entities appear at second trimester or at the early phases of third trimester.^[2]

When round ligament enters into inguinal canal, it also brings along some periton and if this structure encysts during maturation phase, the cyst of the canal of Nuck, which engages in the differential diagnosis with inguinal cystic masses, is formed.^[7]

In our case, wider varicose structures become more evident with Valsalva maneuver. Particularly, ambulatory examination or Valsalva maneuver has critical significance for not overlooking the diagnosis in mild cases.

The treatment of round ligament varicosities is conservative, because it regresses spontaneously during postpartum period.^[8] The treatment of symptomatic inguinal hernias can be surgical at second trimester. Differential diagnosis is very important at this point.

When thrombosis develops as a complication, it may mimic strangulated inguinal hernia. In our case, there was no intraluminal echogenicity which made us suspect thrombus.

Conclusion

In order to avoid unnecessary operation, superficial tissue ultrasonography and Doppler ultrasonography are recommended for pregnant cases who apply with the complaint of inguinal mass. Ultrasonographic examination is not only important for diagnosis but also for the follow-up in terms of the development of thrombosis or rupture.

Conflicts of Interest: No conflicts declared.

References

1. Lee DK, Bae SW, Moon H, Kim YK. Round ligament varicosities mimicking inguinal hernia in pregnancy. *J Korean Surg Soc* 2011;80:437-9.
2. Ryu KH, Yoon JH. Ultrasonographic diagnosis of round ligament varicosities mimicking inguinal hernia: report of two cases with literature review. *Ultrasonography* 2014;33:216-21.
3. Cheng D, Lam H, Lam C. Round ligament varices in pregnancy mimicking inguinal hernia: an ultrasound diagnosis. *Ultrasound Obstet Gynecol* 1997;9:198-9.
4. Smith P, Heimer G, Norgren A, Ulmsten U. The round ligament: a target organ for steroid hormones. *Gynecol Endocrinol* 1993;7:97-100.
5. Salati SA. Round ligament varicosities mimicking inguinal hernia in pregnancy – a diagnostic dilemma. *Afr J Reprod Health* 2011;15:163-4.
6. Uzun M, Akkan K, Coşkun B. Round ligament varicosities mimicking inguinal hernias in pregnancy: importance of color Doppler sonography. *Diagn Interv Radiol* 2010;16:150-2.
7. Okur MH, Halil T, Kaplan S. Nuck kanal kisti: iki olgu sunumu. *Van Tıp Dergisi* 2013;20:25-7.
8. Leung JL. Round ligament varicosities: a rare cause of groin swelling in pregnancy. *Hong Kong Med J* 2012;18:256-7.