

# Placenta Percreta: A Case Report

Ender Yumru, Murat Bozkurt, Faruk Özdemir, Tahsin Ayanoglu, Pınar Tuzlalı

*Clinics of Gynecology and Obstetrics, Taksim Training and Research Hospital, Istanbul*

## Abstract

**Aim:** To review a case of placenta percreta.

**Case:** A case of placenta previa related vaginal bleeding on third trimester was operated and in the operation placenta percreta and an uncompleted rupture was seen and then a subtotal hysterectomy was applied. During the operation an acute hemorrhage was seen. Fluid therapy and blood transfusion was administered. The pathologic examination revealed that it was a placenta percreta.

**Conclusion:** In the cases of placenta previa, one must remember the possibility of abnormality of placental adherence.

**Keywords:** Placenta percreta, abnormality of placenta, hysterectomy.

## *Placenta percreta: a case report*

**Amaç:** Plasenta perkreta olgusunun gözden geçirilmesi.

**Olgu:** Üçüncü trimesterde vaginal kanama ile başvuran ve plasenta previa tespit edilen bir olguda operasyon sırasında plasenta perkreta ve inkomplet rüptür nedeniyle subtotal histerektomi uygulandı. Operasyon sırasında akut hemoraji gözlemlendi. Sıvı replasman tedavisi ve kan transfüzyonu uygulandı.

**Sonuç:** Patoloji sonucu plasenta perkreta olarak gelen plasenta previası olan olgularda plasenta yapışma anomalileri akılda tutularak operasyona girilmelidir.

**Anahtar kelimeler:** Plasenta perkreta, plasenta anomalileri, histerektomi.

## Background

Placental adherence anomalies are rare but they may cause solid intraabdominal bleeding by causing spontaneous uterine rupture in second and third trimesters. They are obstetric emergencies and require rapid diagnosis and treatment. It is a situation that characterized by regional or prevalent insufficiency of decidual basalis of placenta creta.<sup>1</sup> It has three types: Placenta accreta vera that villus adheres to myometrium but not spreads inside, placenta increta that villus enters into the myometrium

and placenta percreta that placenta passes myometrium entirely and reaches to serosa.<sup>2</sup>

## Case

F.H. who applied by protocol number 391 to Taksim Training and Research Hospital in 20.03.2003 was 38-year-old and G7 P6 A0 C0. Cesarean operation was applied by anus presentation and fetal distress indication four years ago to this patient who had five normal spontaneous births. The patient who came with vaginal bleeding

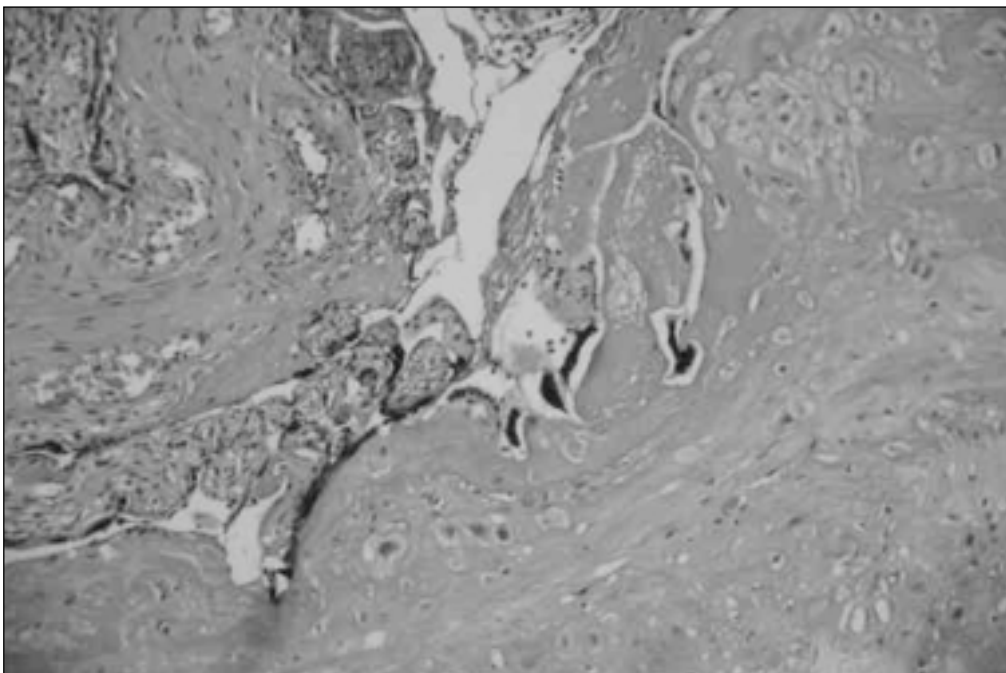
complaint did not remember her last menstrual period. Active vaginal bleeding was observed by applying speculum examination to the patient. Single livable fetus compatible with 37<sup>th</sup> gestational week and total placenta praevia were found in transabdominal ultrasonography. Preoperative hemoglobin was 10g/dL, hematocrit was 29.8%, white sphere count was 13.103, thrombocyte count was 304.103. Arterial blood pressure was 140/55 mmHg and pulse count was 92/min. The case was taken into operation with these diagnoses. Placenta in exploration was totally covering incomplete rupture area under visceral peritoneum. Placenta was adhered to old incision line with its dimension of 10 cm – 7 cm. Female baby who was 2950 gr, 49 cm and having 8 for 1st minute APGAR score was born. Placenta was tried to separate from adherence surfaces by controlling bleeding as possible. It was observed that placenta covered internal os completely. Placenta could not be separated. By considering bleeding increase, subtotal hysterectomy was applied to the case. Hemoglobin was 5.5 g/dL during the operation. By applying four units of blood infusions (two units during the operation and two units after the operation) hemoglobin was increased to 9.1 g/dL. The patient who was applied

antibiotherapy postoperative five days was discharged from hospital on the sixth day as healthy.

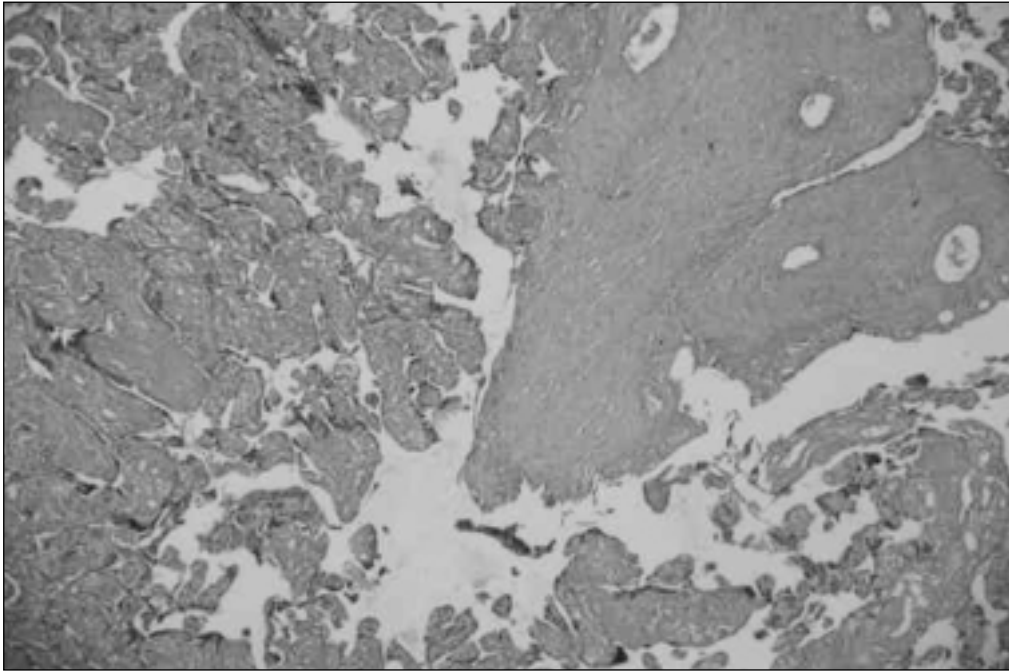
## Discussion

Placenta accreta is the lightest form and 60% of cases have it. 20% of cases have placenta increta and placenta percreta is seen in 20% of cases and it is the most advanced form of it. Chorionic are penetrated to myometrium completely and they spread to close tissues in some cases. Creta is seen frequently in women who had cesarean operation in the past, those who had cicatrix tissue for other reasons, those who were made delivered by hands and pregnant with high parity. More than 30% of cases have also placenta praevia.<sup>3</sup> In our case, there were advanced maternal age, high birth count and cesarean operation applied before as risk factors. Also placenta praevia was found.

Placenta creta may cause over bleeding and frequently requires hysterectomy. 14% of cases are found uterus rupture.<sup>3</sup> Incomplete rupture was found in our case. Even it is rare, invasion of villus to close organs such as bladder. Placenta accreta and advanced kinds increta and percreta are frightening due to the fact that they cause more serious maternal complications. Even some abdominal hysterectomies could not help to save patients lives.



**Figure 1.** Histopathologic section from placental adherence.



**Figure 2.** Histopathologic section from placental adherence.

Placenta praevia which is defined as partially or completely covering os intern by placenta is an important reason for bleedings of third trimester and it is observed less than 12% of births.<sup>4</sup> It is reported that invasive placentation and placenta praevia are seen together in 2/3 of cases and it is found that 1/4 of them had cesarean before.<sup>5</sup>

It is hard to diagnose placenta percreta antenatally. Loss of normal hypoechoic zone of retroplacental myometrium ultrasonographically, thinning of hyperechogenicity between uterus serosa and bladder and existence of focal exophytic mass which reminds invasion to near organs especially to bladder may help to diagnosis.<sup>6</sup>

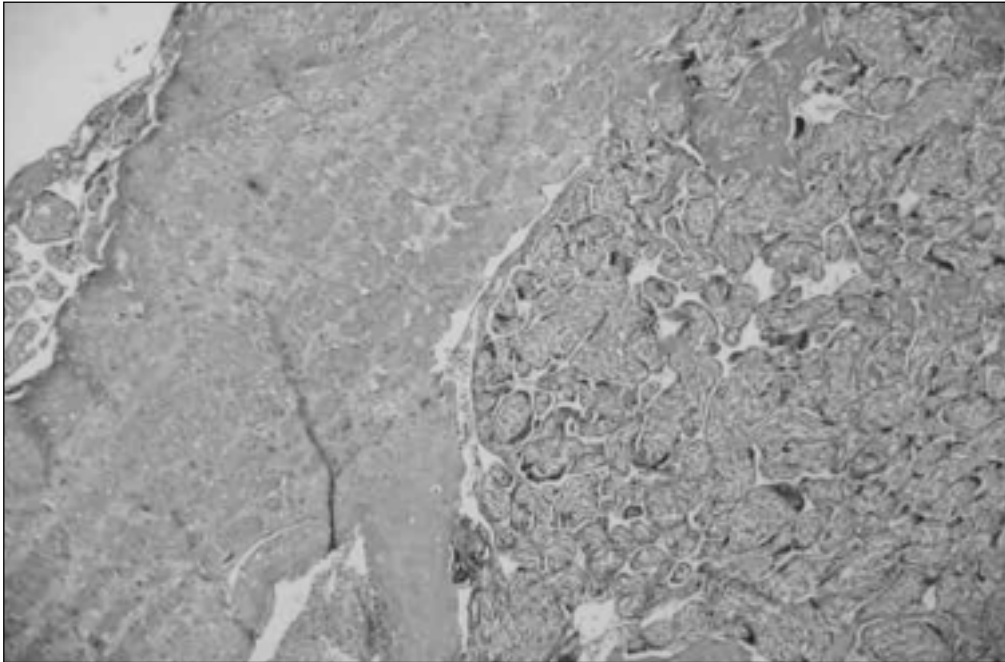
There were vascular holes which may remind us placenta percreta in our case.<sup>7</sup>

Magnetic resonance display may show the invasion of placenta to myometrium but it should be evaluated by experienced people.<sup>7</sup>

Chou et al found extraordinary uteroplacental vascular net by three dimensional colored Doppler sonography in patients who had placenta praevia increta/percreta. They reported that this situation

called as neovascularization may be used in diagnosis.<sup>8</sup>

Zelop et al examined the relationship between MSAFP increased in third trimester and abnormal placental adherence. They applied hysterectomy to 11 patients who had placenta adherence anomaly and applied cesarean operation to 14 patients who were chosen as control group and had placenta praevia but had not adherence anomaly. While increased MSAFP was observed 5 of 11 cases who had placenta adherence anomaly, they found normal MSAFP in 14 patients within control group.<sup>9</sup> Increased serum creatine kinase may be helpful in diagnosis.<sup>10</sup> Actual diagnosis is made as pathologically. In our case, approximately 4 cm perforation and placenta praevia were found in left upper half of cervix macroscopically. Invasion of placental chorion villus structures directly to myometrium was seen in microscopic pathology but no decidual basalis was found near it. Also, hyaline muscle tissue focuses and fibrin areas were observed between them. It was seen that trophoblastic cells penetrated myometrium completely and reached to perimetrium.



**Figure 3.** Histopathologic section from placental adherence.

Treatment of placenta percreta is hysterectomy. Rabenda-Lacka et al reported that 0.021% of normal births and 1.03% of cesarean operations required hysterectomy. Placenta adherence anomalies with 61.1%, uterine atony with 13.8% and uterine rupture with 11.1% constituted hysterectomy indications in this work. Most frequent complication couple with 5.6% was shock and urinary injuries. Maternal mortality was found as 2.8%.<sup>11</sup> Placenta percreta cases which is hemodynamically stable may be treated by methotrexate conservatively.<sup>12</sup> It becomes frequently used method in cases that want to protect fertility of uterine artery embolization

### Conclusion

Even it is rare, placenta percreta gradually increases due to applying cesarean operation to more women. During ultrasonography, myometrium and placenta wall in these cases should be evaluated in detail. Creatine kinase and maternal serum alpha-fetoprotein may help to other diagnosis for directing diagnosis. While the treatment is hysterectomy for patients who finished fertility, it is

uterine artery embolization for patients want to have child or it is methotrexate treatment for placenta leaved on its own location after operation.

### References

1. Fox H. Pathology of the placenta. Philadelphia. Saunders; 1978.
2. Fleischer. Obstetrik ve Jinekolojide Sonografi. A. Yüksel. 2000.
3. Fox H. General pathology of the placenta. In: Fox H, ed. Hainers and Taylor Obstetrical and Gynaecological Pathology. 3 rd ed. Edinburg: Churchill-Livingstone; 1987; 972-1000.
4. Iyasu S, Saftlas AK, Rowley DL, et al. The epidemiology of placenta previa in the United States, 1979 through 1987. *Am J Obstet Gynecol* 1993; 168: 1424.
5. Read JA, Cotton DB, Miller FC. Placenta accreta: Changing clinical aspects and outcome. *Obstet Gynecol* 1980; 56; 31.
6. Guy GP, Peisner DB, Timor-Tritsch IE. Ultrasonographic evaluation of uteroplacental blood flow patterns of abnormally located and adherent placentas. *Am J Obstet Gynecol* 1990; 163: 723.
7. Lam G, Kuller J, Mc Mahon M. Use of magnetic resonance imaging and ultrasound in the antenatal diagnosis of placenta accreta. *J Soc Gynecol Investig* 2002; 9: 37-40.
8. Chou MM, Tseng JJ, Ho ES, Hwang JI. Three-dimensional color power Doppler imaging in the assessment of uteroplacental neovascularization in placenta previa increta/ percreta. *Am J Obstet Gynecol* 2002; 187: 515- 6.
9. Zelop C, Nadel A, Frigoletto FD Jr, Pauker S, Mac Millan M. Placenta accreta/ percreta/ increta a cause of elevated ma-

- ternal serum alpha- fetoprotein. *Obstet Gynecol* 1992; 80: 693- 4.
10. Ophir E, Tendler R, Odeh M, Khouri S, Oettinger M. Creatine kinase as a biochemical marker in diagnosis of placenta increta and percreta. *Am J Obstet Gynecol* 1999, 180: 1039-40.
  11. Rabenda-Lacka K, Wilezynski J, Radoch Z, Breborowicz GH. Obstetrical hysterectomy. *Arch Gynecol Obstet* 2001; 265: 89-90.
  12. Butt K, Gagnon A, Delilse MF. Failure of methotrexate and internal iliac balloon catheterization to manage placenta percreta. *Obstet Gynecol* 2002; 99: 981-2.